UBC Department of Urologic Sciences Lecture Series

Department of
UROLOGIC SCIENCES
UBC

UBC

Urological Trauma

Disclaimer:

- This is a lot of information to cover and we are unlikely to cover it all today
- These slides are to be utilized for your reference to guide your self study

Department of
UROLOGIC SCIENCES
UBC

MCC Objectives

http://mcc.ca/examinations/objectives-overview/

For LMCC Part 1

Objectives applicable to this lecture:

- Urinary Tract Injuries
  - Kidney
  - Bladder and Urethra

Objectives

Trauma:

1. Given a patient with a potential urinary tract injury:
   1. To list and interpret key clinical findings
   2. To list and interpret critical investigations
   3. Construct an initial management plan

Systems:

- Renal
- Bladder
- Urethra
- Ureter
- External Genitalia

Department of
UROLOGIC SCIENCES
UBC

Case #1

- 55 year old healthy male in MVA, T-boned, high speed
- Brought in by ambulance
- ABCs done, c-spine cleared
- GCS 8
- **Presents with gross hematuria**
  - DDx and sites of bleeding?

Case # 1 cont'd

- Potential Causes of Hematuria:
  - Urethral Injury
  - Bladder Injury
  - Ureteric Injury
  - Renal Injury

Department of
UROLOGIC SCIENCES
UBC

RENAL TRAUMA

Renal Trauma Overview

- Most commonly injured GU organ
- 10% of all serious injuries abdominal have associated renal injury
- Variable etiology depending on the area
  - Rural: 80-95% blunt
  - Urban: as little as 15% blunt

Department of
UROLOGIC SCIENCES
UBC

Hematuria and Renal Injury

- NOT related to the degree of injury

Gross Hematuria is Variable:

- 1/3rd of patients with renovascular injuries
- 24% of patients with renal artery occlusion
- Only 63% of Grade IV injuries (4% have no hematuria whatsoever!)

Department of
UROLOGIC SCIENCES
UBC

Whom to workup

- Penetrating trauma: EVERYONE
- Blunt trauma: Image with CT if:
  - gross hematuria
  - microhematuria plus shock
  - microhematuria plus acceleration/deceleration

Mee et al. (1989)

Hardeman et al (1987)

Department of
UROLOGIC SCIENCES
UBC

Imaging of trauma patient with hematuria

- CT preferred
  - With contrast
  - With “delayed” films (mandatory)
  - Why not get CT cystogram too?
- Standard intravenous pyelogram (IVP): Forget it
- “One Shot” intraoperative IVP
  - 2 cc/kg intravenous contrast
  - Single film at 10 minutes

Department of
UROLOGIC SCIENCES
UBC

Intraoperative One Shot IVP

- Allows safe avoidance of renal exploration in 32%
  (Morey et al, 1999)
- Highly specific for urinary extravasation
- Confirms existence of the other kidney

Fig. 15.4.8. One-shot IVP revealing a nonfunctioning right kidney

Department of UROLOGIC SCIENCES UBC

Indications for renal trauma surgery

- **Absolute**
  - Grade V renal injury (debatable in blunt trauma): NEPHRECTOMY or REPAIR
  - Vascular injury in a single kidney: Vascular repair
- **Relative**
  - Persistent bleeding > 2 units/day
  - Devitalized segment AND urinary extrav (80% complication rate?)
  - Renal pelvis injury
  - Ureter injury
  - Incomplete staging and ongoing laparotomy
  - Grade IV vein or artery (thrombosis): nephrectomy

- Most penetrating renal injuries

Department of UROLOGIC SCIENCES UBC

AAST Organ Injury Severity Scale for the Kidney

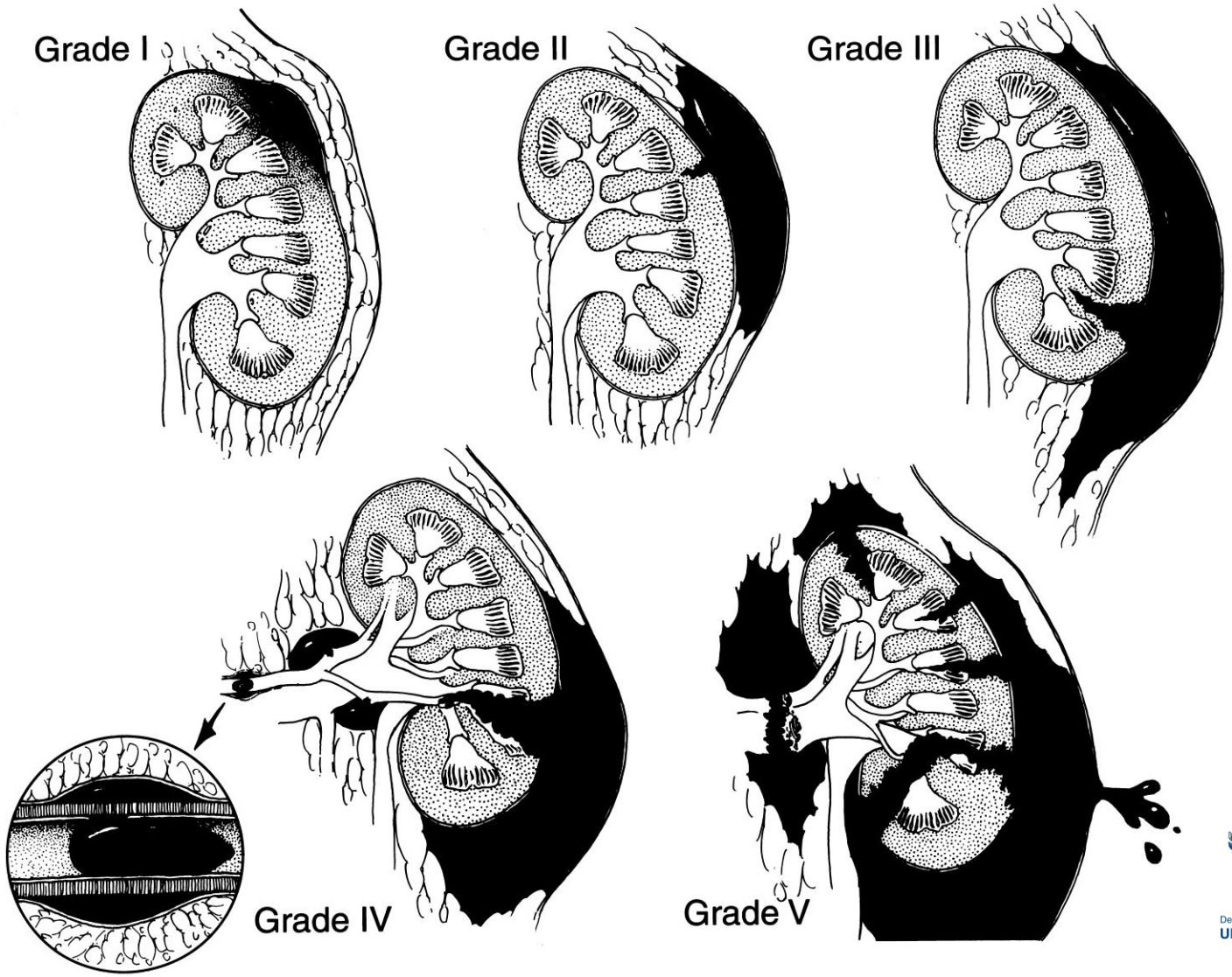

Department of
UROLOGIC SCIENCES
UBC

AAST Organ Injury Severity Scale for the Kidney

Department of UROLOGIC SCIENCES UBC

Table 19

Kidney injury scale

Grade*	Type of injury	Description of injury	ICD-9	AIS-90
I	Contusion	Microscopic or gross hematuria, urologic studies normal	866.01	2
	Hematoma	Subcapsular, nonexpanding without parenchymal laceration	866.11	2
II	Hematoma	Nonexpanding perirenal hematma confirmed to renal retroperitoneum	866.01 866.11	2
	Laceration	<1.0 cm parenchymal depth of renal cortex without urinary extravagation	866.02 866.12	2
III	Laceration	<1.0 cm parenchymal depth of renal cortex without collecting system rupture or urinary extravagation	866.02	3
IV	Laceration	Parenchymal laceration extending through renal cortex, medulla, and collecting system	866.12	4
	Vascular	Main renal artery or vein injury with contained hemorrhage		4
V	Laceration	Completely shattered kidney	866.03	5
	Vascular	Avulsion of renal hilum which devascularizes kidney	866.13	5

*Advance one grade for bilateral injuries up to grade III
From Moore et al. [7]; with permission


33.8cm
V 120
A 280~

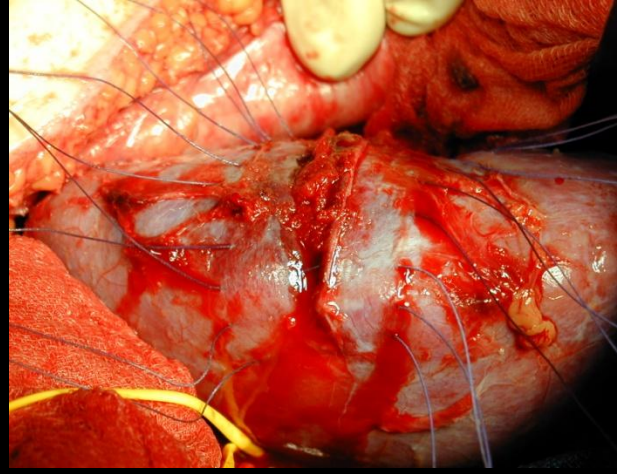

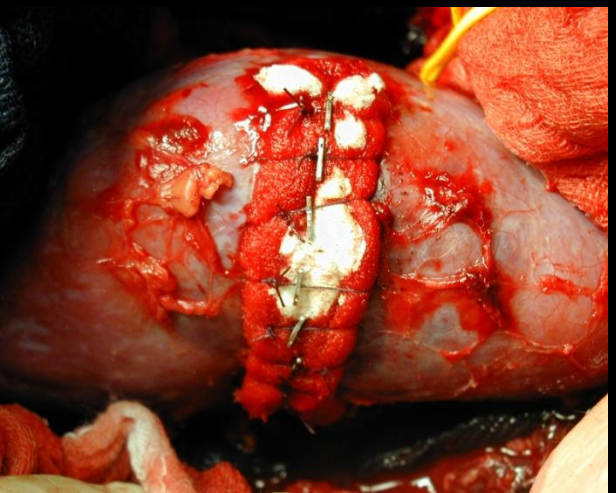

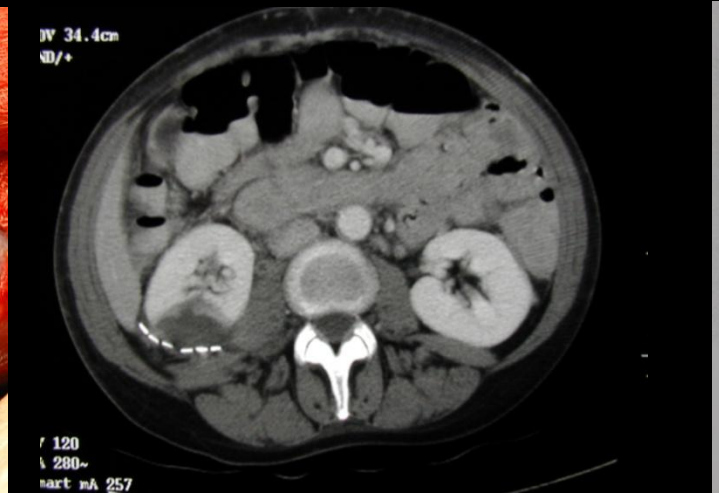
34.4cm
120
280~
mart mA 257

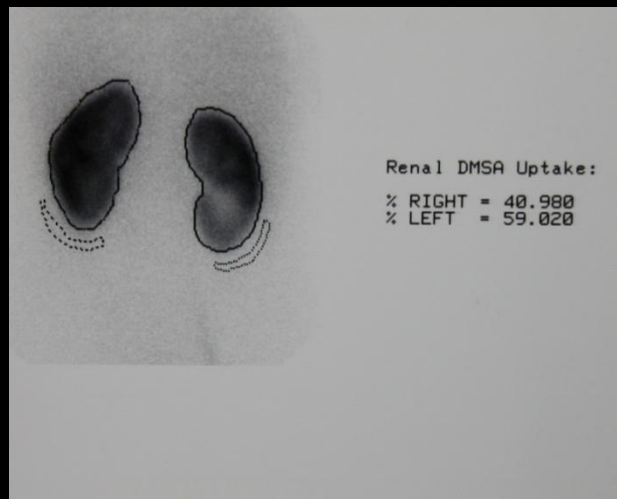
Renal DMSA Uptake:
% RIGHT = 40.980
% LEFT = 59.020

Case

- 34 year old man flipped over handlebars of mountain bike
- Gross hematuria
- Stable
- Investigations?

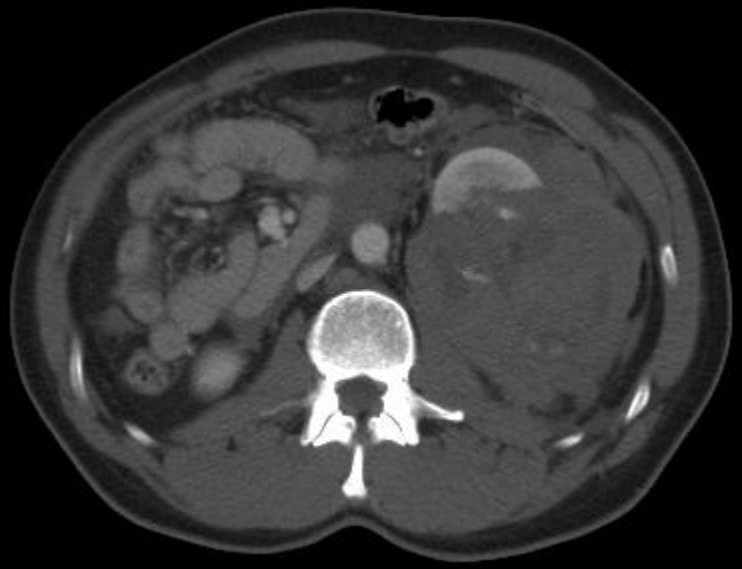

Case

- Patient continues to be febrile
- Hgb drifts down to 70 after 3 U PRBCs
- Management?

Management Options For Renal Trauma

- Close observation
  - Bed rest
  - Serial Hemoglobins
  - Antibiotics if urinary extravasation
- Radiographic Embolization
- Urinary Diversion
  - Ureteral Stenting
  - Nephrostomy Drainage
- Surgery
  - Renal Preservation / Reconstruction
  - Nephrectomy

Department of
UROLOGIC SCIENCES
UBC

Bladder Trauma

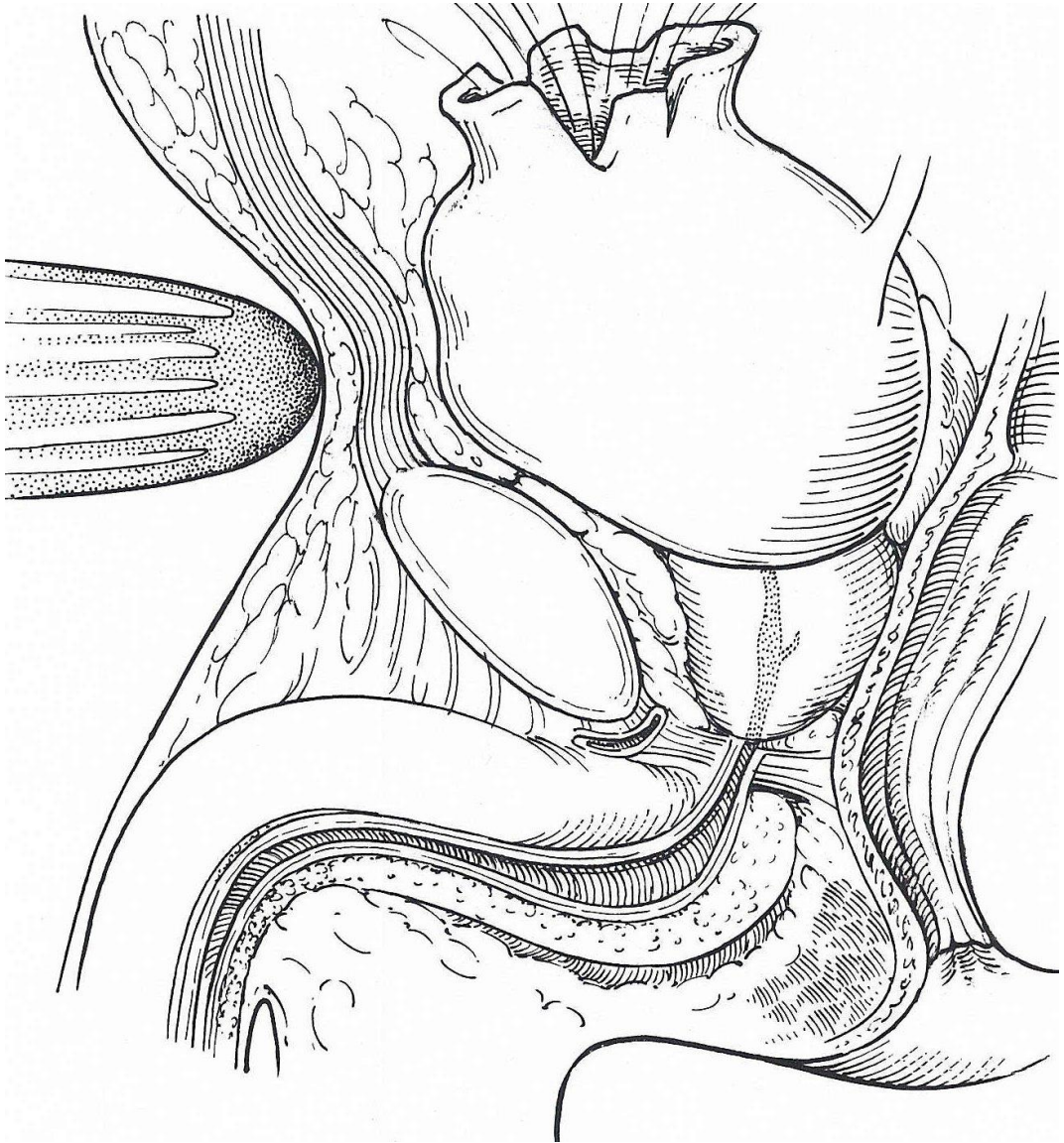

Department of
UROLOGIC SCIENCES
UBC

Bladder: BLUNT: Overview

- Rare: <2% of all injuries requiring surgery
- Often with a severe associated injuries
- Often high-energy injuries
- Associated with urethral rupture 10-29% and pelvic fracture 6-10%

Department of
UROLOGIC SCIENCES
UBC

Bladder: PENETRATING: Overview

- **Civilian incidence 2%**
- **Associated major abdominal injuries (35%) and shock (22%)**
- **Mortality high: 12%**

Bladder: Diagnosis: Physical Signs

- Suspicion: required in cases of penetrating trauma (no time for studies): based on trajectory
- Physical signs:
  - Abdominal pain
  - Abdominal tenderness
  - Abdominal bruising
  - Urethral catheter does not return urine
  - Delayed?
    - Fever
    - No urine output
    - Peritoneal signs
    - ↑ BUN / Creatinine

Department of UROLOGIC SCIENCES UBC

Bladder: Diagnosis: Hematuria

- Most (95%) have gross hematuria
- Microhematuria does occur: usually with minimal injury

Bladder: Diagnosis Plain Cystography

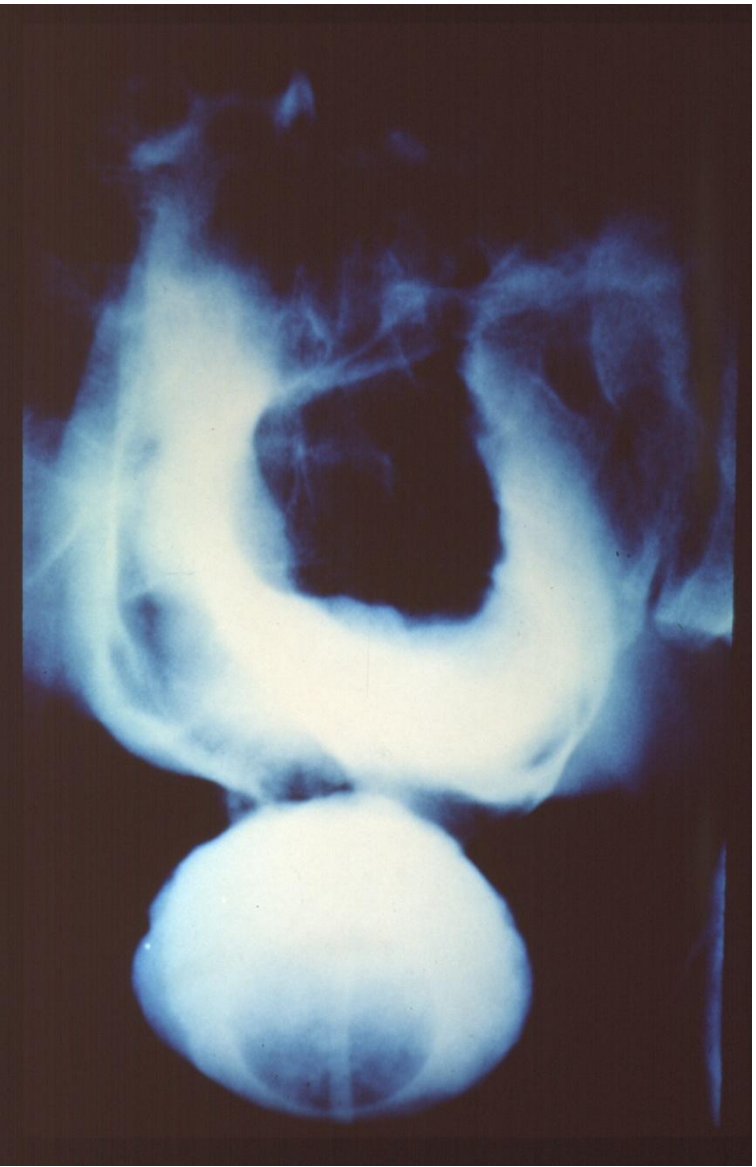

- Nearly 100% accurate when done properly:
  - Adequate filling with 350 cc
  - Drainage films
- Use 30% contrast
- Underfilling (250 cc) associated with false negatives

Department of UROLOGIC SCIENCES UBC

Bladder: Diagnosis CT Cystography

- Preferred, especially if already getting other CTs
- <u>Antegrade filling by “clamping the Foley” is not OK!</u>
- Must dilute contrast (6:1 with saline, or to about 2-4%)

Department of
UROLOGIC SCIENCES
UBC

Bladder: Diagnosis CT Cystography

Extraperitoneal

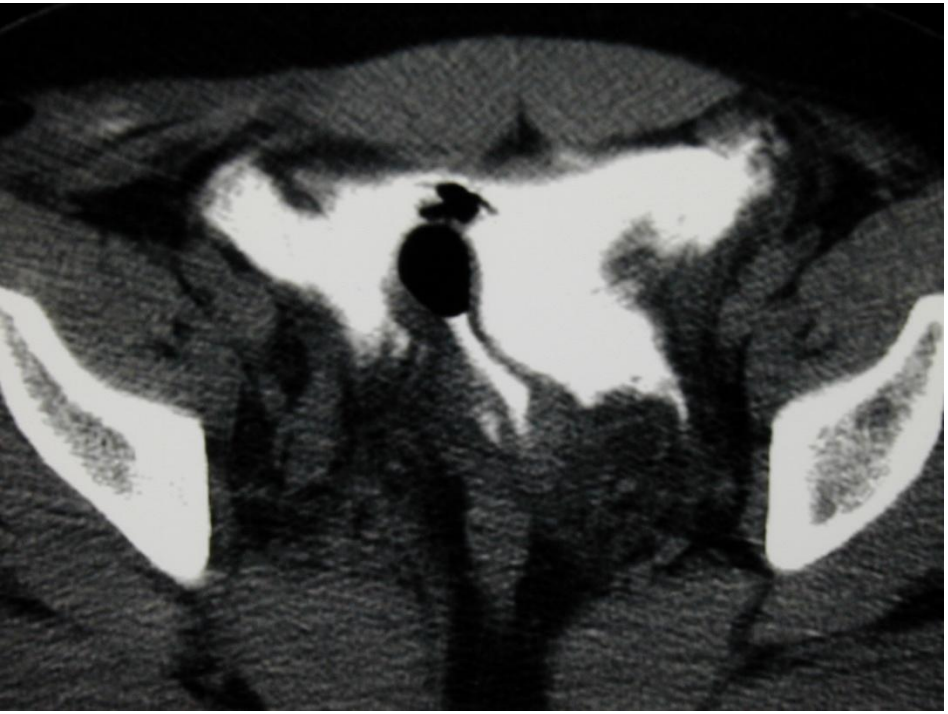

Intraperitoneal

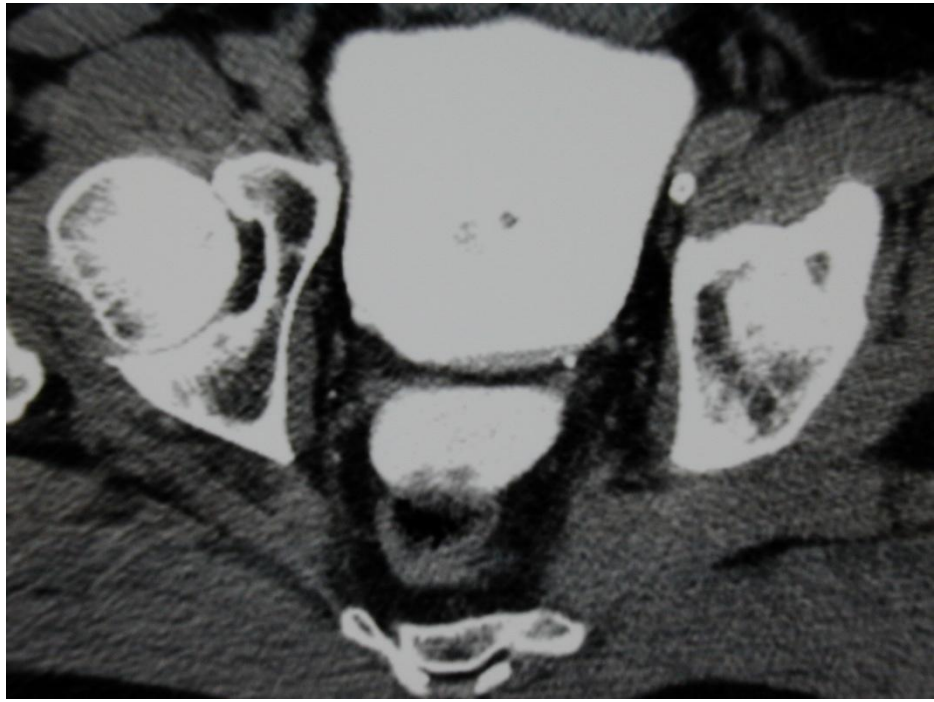

Posterior Urethral Injuries

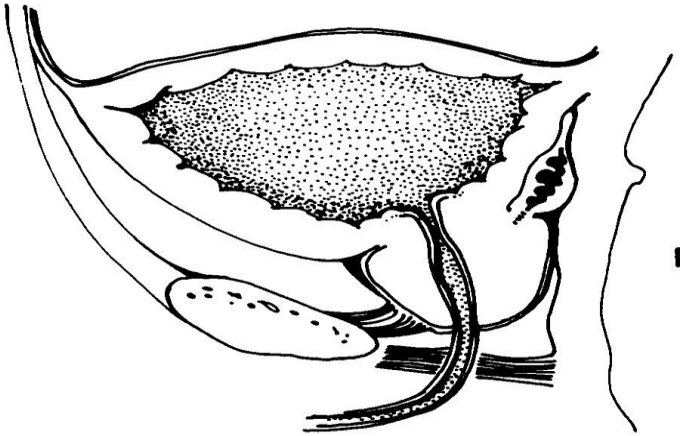

NORMAL POSITION

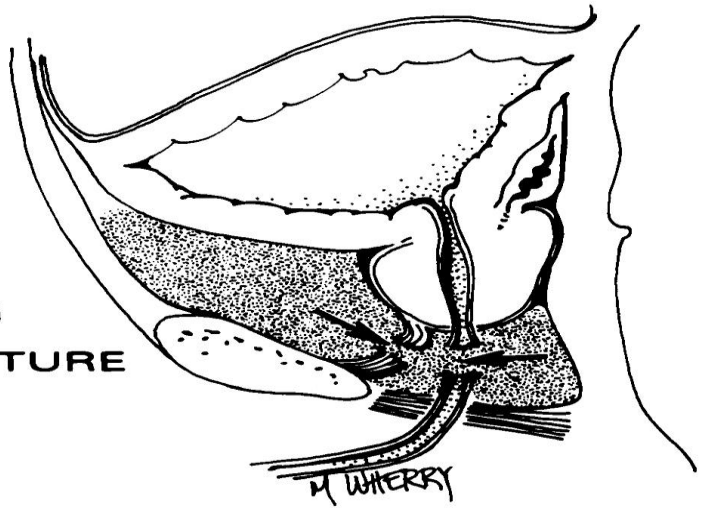

FOLLOWING
COMPLETE RUPTURE

Posterior Urethra Trauma: Etiology

- 4-14% of pelvic fractures
- Bilateral pubic rami fractures (straddle fracture) and sacroiliac diasthasis
- Mostly males, but can happen in females
- Associated bladder rupture in 10-17%
- Rectal injury can lead to urethral-rectal fistula in 8%

Department of
UROLOGIC SCIENCES
UBC

Posterior Urethra Trauma: Diagnosis

- Blood at meatus: 50%
- “High riding prostate”: 34%
- Inability to urinate
- Inability to place urethral catheter
- Rarely, perineal hematoma (late finding)

Department of
UROLOGIC SCIENCES
UBC

Retrograde Urethrogram

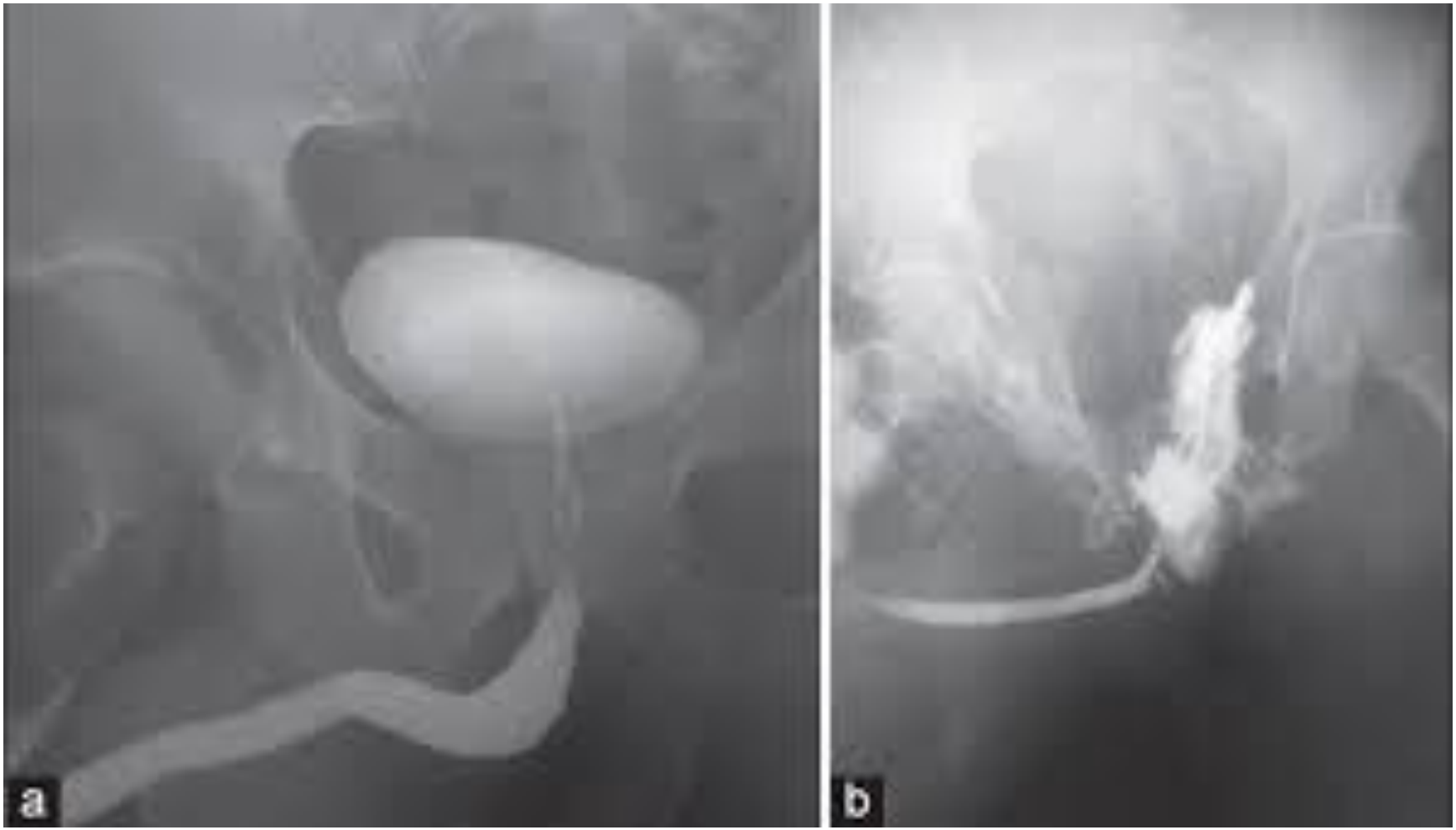

Normal

Urethral Injury

RUG

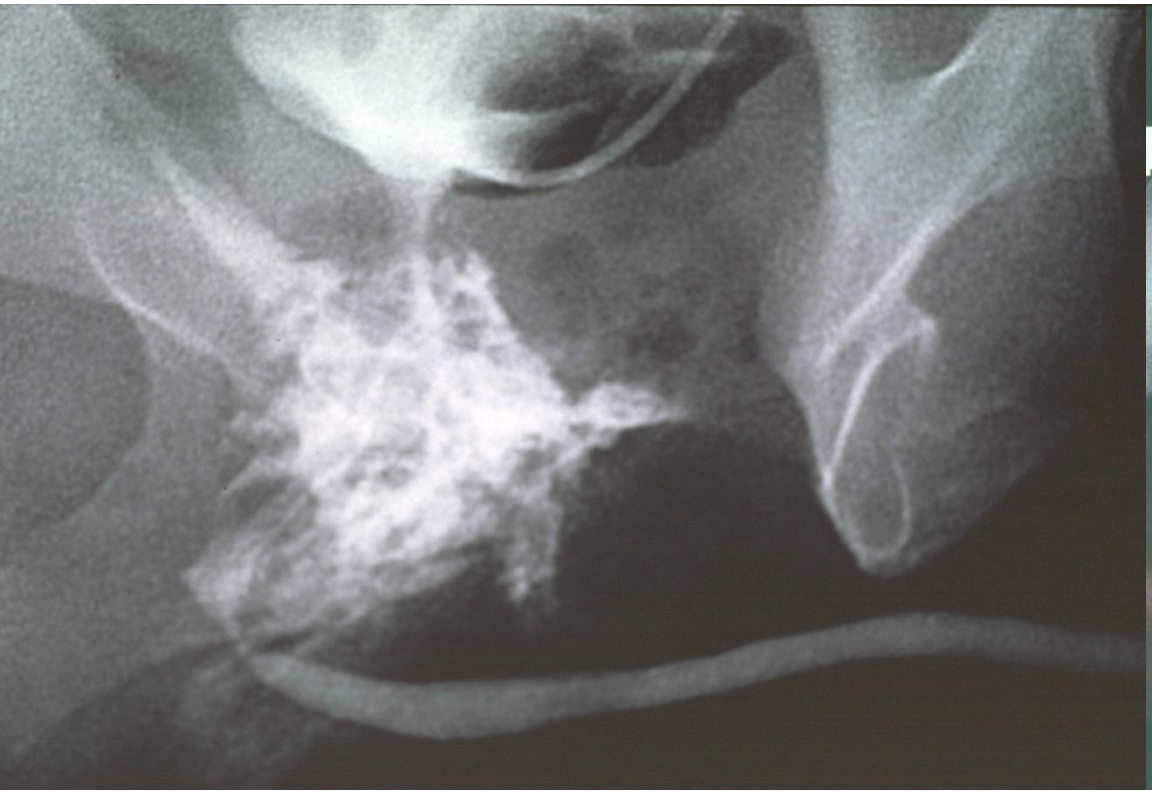

Cysto View

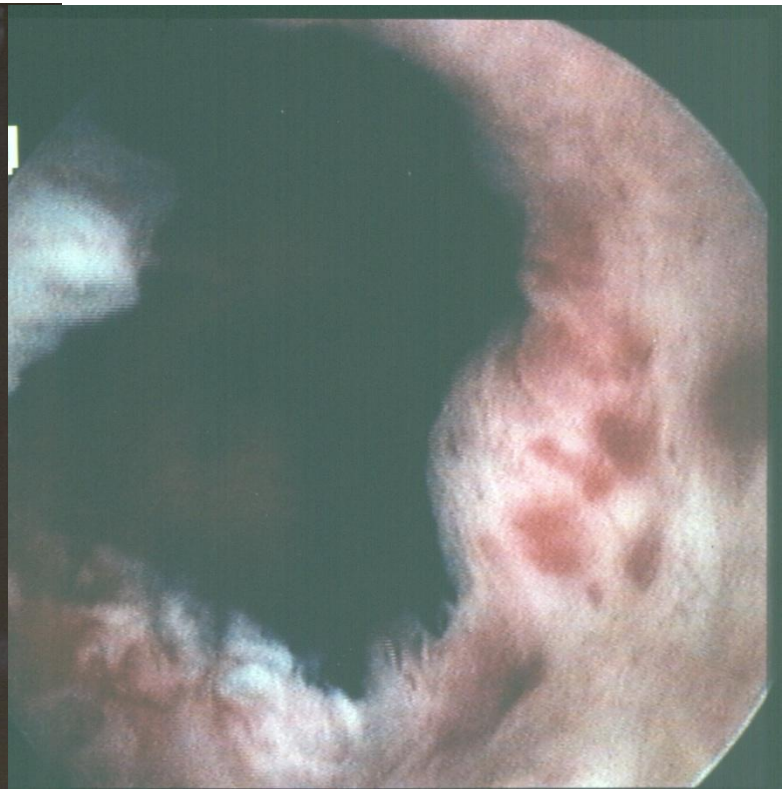

Department of
UROLOGIC SCIENCES
UBC

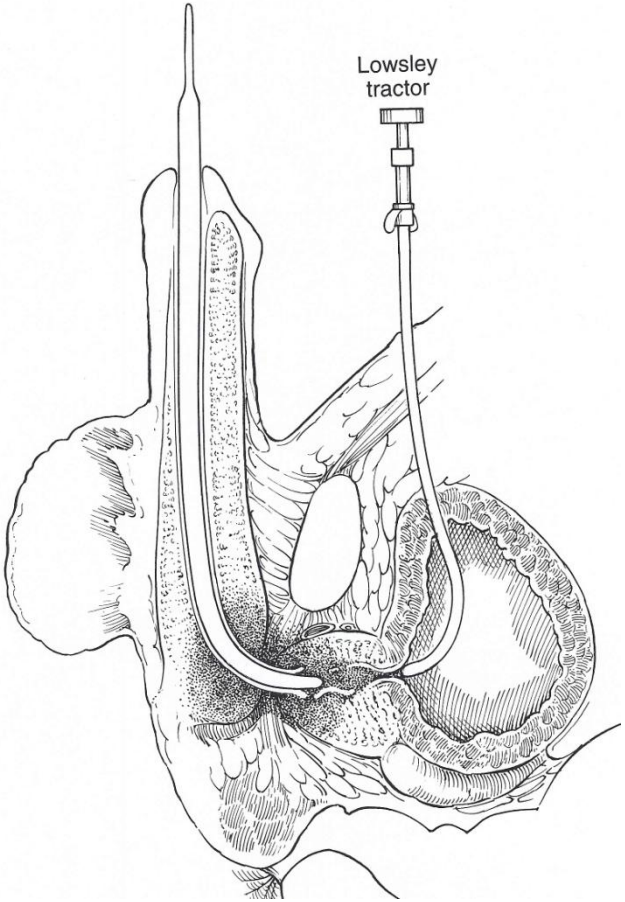

Department of
UROLOGIC SCIENCES
UBC

Posterior Urethra Trauma: Management

- Unable to get Foley in: Place an open suprapubic catheter
- Allows inspection/repair of the bladder for associated injury
- No evidence that s/p “infects orthopedic hardware” although ortho docs worry about it

Department of
UROLOGIC SCIENCES
UBC

External genital trauma

Testes Trauma

- Rare in general
- But, in significant scrotal blunt trauma, rupture can be as high as 50%
- Bilateral 1.5%
- Assaults and sports injuries predominate
- Local anesthetic block may improve exam

Repair Repair Repair Repair

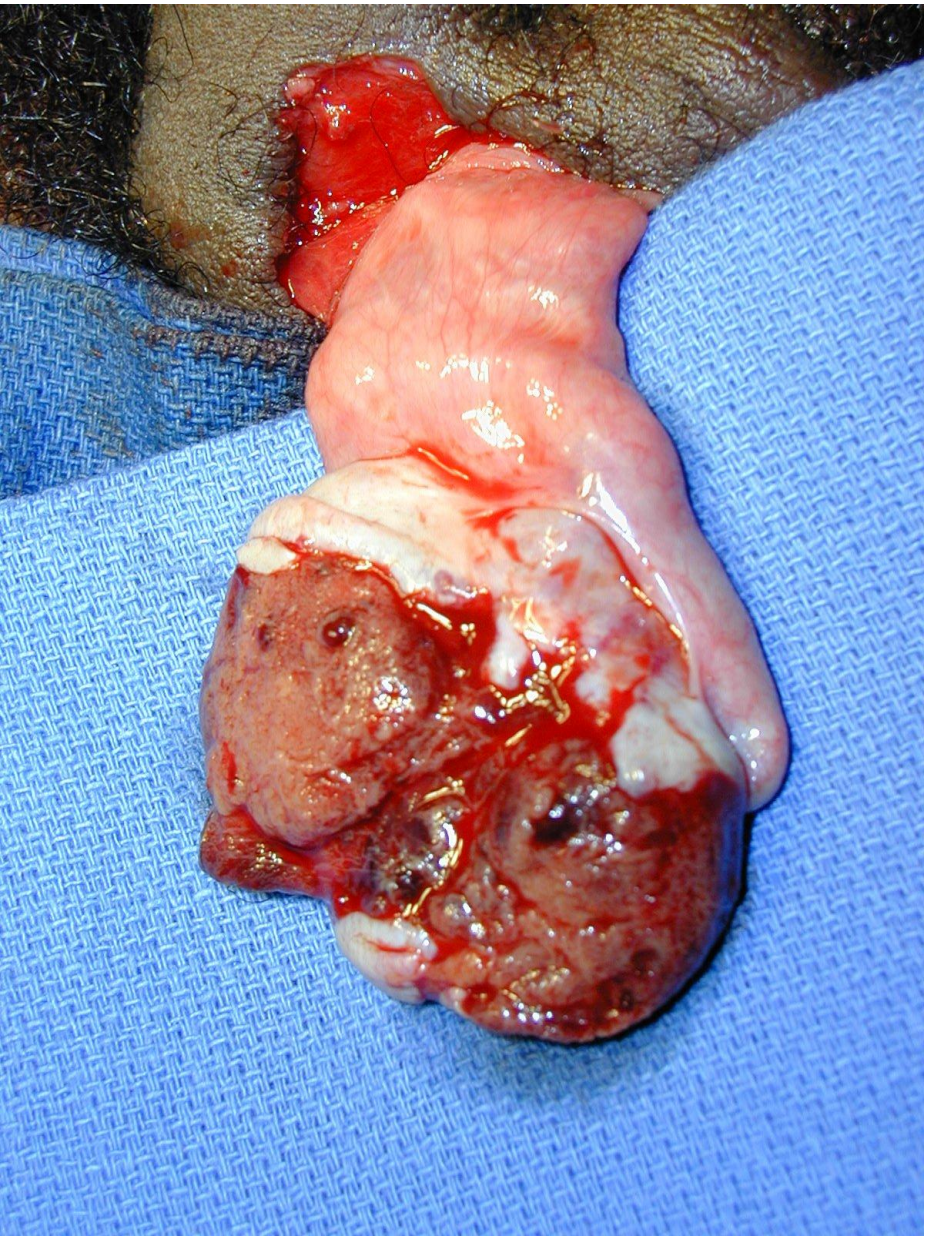

Case #2

- 34 y.o. male in high velocity MVA presents to ER
- GCS 13, ABCs OK
- “cannot void”
- Tib-fib, Pelvic #, multiple rib #s and pulmonary contusions
- Next step?

Case # 2

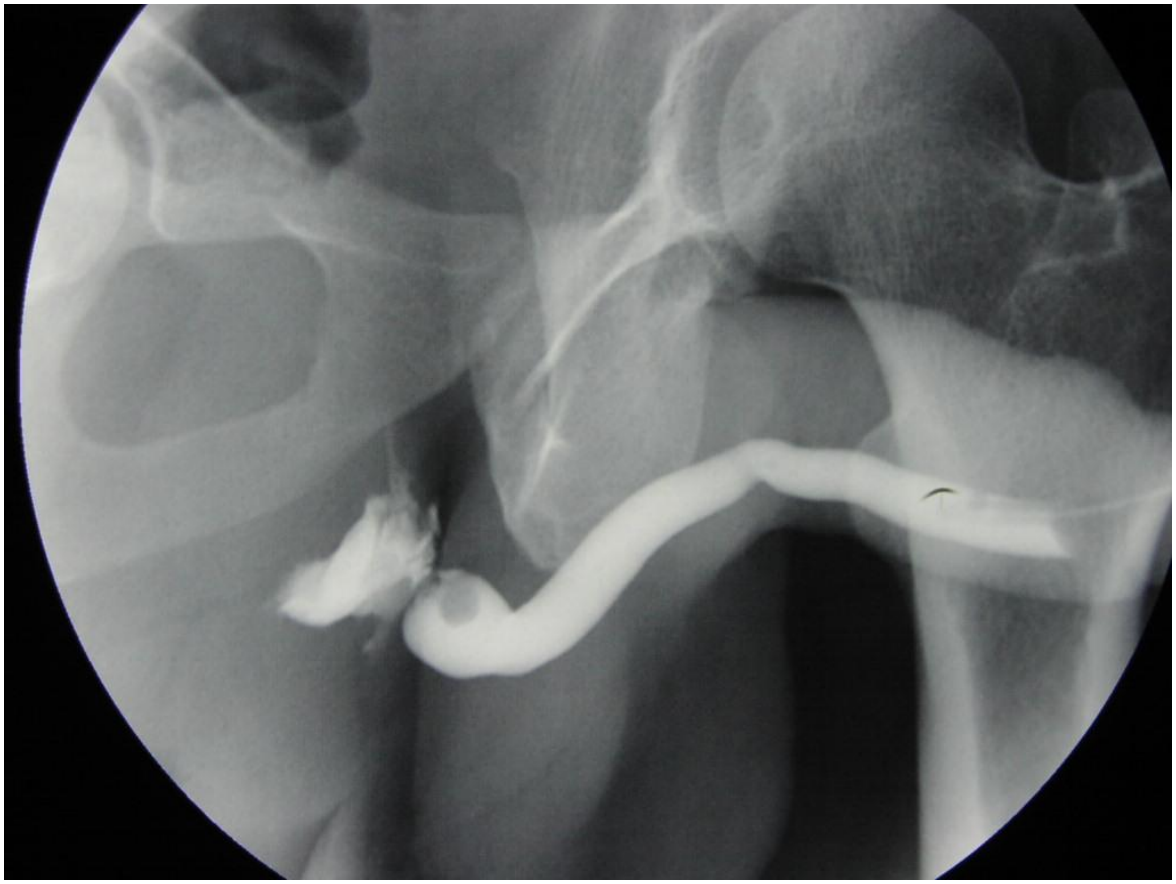

Department of
UROLOGIC SCIENCES
UBC

We get all sorts of calls….

Department of
UROLOGIC SCIENCES
UBC

Main points : Kidney Trauma

- Get a CT in everyone with
  - Gross hematuria
  - Microhematuria + deceleration or shock
- Treat most kidneys nonoperatively
- Indications for operation:
  - Grade V renal injury
  - Persistent bleeding
  - Suspected ureter or collecting system injury
  - Incomplete staging and ALREADY having lap
- Isolate the vessels first

Department of
UROLOGIC SCIENCES
UBC

Main Points: Bladder Trauma

- Get a CT cystogram if pelvic fracture
- Most extraperitoneal ruptures can be managed conservatively,
  - BUT: Consider treating extraperitoneal bladder ruptures OPEN, especially if undergoing lap and DEFINITELY if undergoing pelvic ORIF
- Microhematuria (no gross hematuria) usually means no significant injury to bladder

Main Points: Ureter/Urethra

- Suspect ureter injuries and you'll miss them less
- If the Foley isn't draining, it's probably not in the right place