

UBC Department of Urologic Sciences Lecture Series



Hematuria Urothelial Tumours Renal Masses Urolithiasis





Disclaimer:

- This is a lot of information to cover and we are unlikely to cover it all today
- These slides are to be utilized for your reference to guide your self study



MCC Objectives

<http://mcc.ca/examinations/objectives-overview/>

For LMCC Part 1

Objectives applicable to this lecture:

- Blood in Urine/Hematuria

Objectives

Hematuria:

1. To provide a framework for you to understand the initial workup and management of patients presenting with hematuria
2. To discuss some common pathologies associated with hematuria and their risk factors, and management
 1. Urothelial tumours
 2. Renal Tumours
 3. Urolithiasis

Hematuria

- 65 year old male presents with a 2 day history of gross painless hematuria.

Hematuria

- 65 year old male presents with a 2 day history of gross painless hematuria.



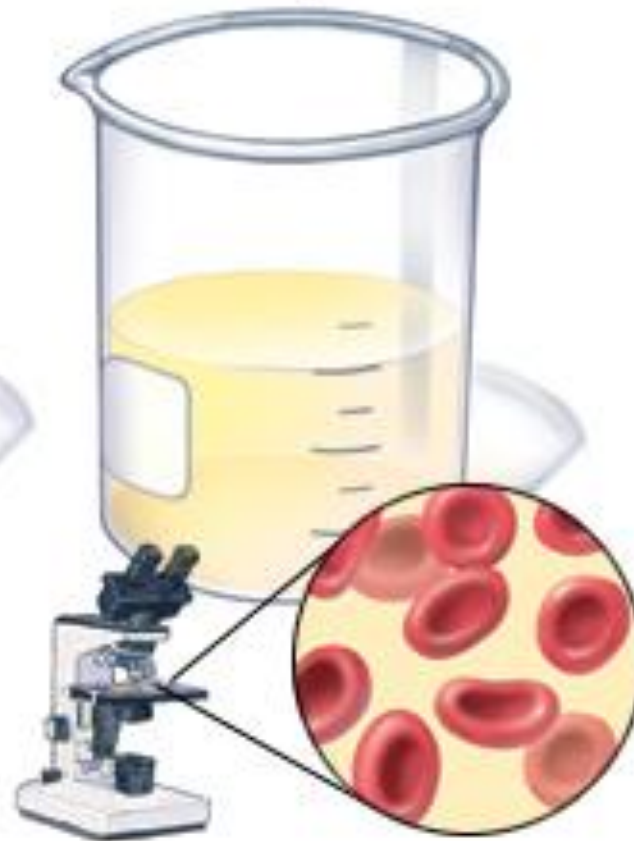- Important Points to Know
 - How to take a history in patient with hematuria
 - What are the most common causes?
 - Risk factors that this could be something worrisome?
 - How do I work this patient up?
 - When should I refer to a urologist?

Hematuria

Gross hematuria



Microscopic hematuria



Hematuria

Gross hematuria



~25% chance of urologic malignancy

Microscopic hematuria



~5% chance of urologic malignancy

Hematuria General Approach

Hematuria

Pre-renal

- Coagulation disorders
- Pseudohematuria
 - (beets, dyes, laxatives)

Renal

- Stones
- Trauma
- Tumours
- Infection
- Glomerulonephritides
- Vascular Malformations

Post Renal

- Stones
- Trauma
- Tumours
- Infection

Hematuria

- Take home message #1
 - The most common urologic causes of hematuria
 - Stones
 - Trauma
 - Tumour
 - Infections

Hematuria

- Etiology by Age

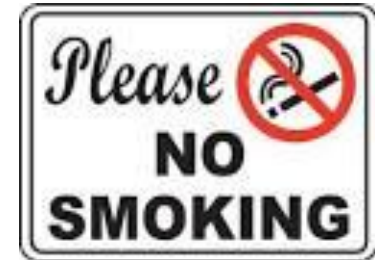Age	Etiology in order of frequency
0-20	Glomerulonephritis, UTI, congenital anomalies
20-40	UTI, stones, bladder tumor
40-60	Male: Bladder tumor, stones, UTI Female: UTI, stones, bladder tumor
>60	Male: BPH, bladder tumor, UTI Female: Bladder tumor, UTI

Hematuria History

- What questions should you ask this patient?
 - Stone
 - Flank/Abdominal pain, dysuria, previous stones
 - Trauma
 - Recent encounters with Chuck Norris
 - Tumour
 - Weight loss, night sweats, flank pain, voiding changes
 - Risk factors ?????
 - Infection
 - Suprapubic pain, dysuria, frequency, fever/chills +/- flank pain

Risk Factors for Urothelial Tumours

- Smoking
- Smoking
- Smoking
- Occupational exposures: Aniline dyes
 - Hairdressers, leather tanners, textile workers, painters, dry cleaners
- Medications
 - Phenacetin – older analgesic, common in australiaasia
 - Cyclophosphamide
- Previous radiation exposure
- Chronic cystitis: catheters, infections



Hematuria

- Take home message #2
 - Gross, painless hematuria is a malignancy until proven otherwise

Hematuria

- Take home message #2
 - Gross, painless hematuria is a malignancy until proven otherwise!
 - Stones, trauma, infections usually are symptomatic
 - Anticoagulation / coagulopathy are not sufficient reasons for gross hematuria

Hematuria

- 65 year old male presents with a 2 day history of gross painless hematuria. He is a long term 2 pack per day smoker. He works as a hairdresser part-time, and part-time at a dry cleaners.

Hematuria

- 65 year old male presents with a 2 day history of gross painless hematuria. He is a long term 2 pack per day smoker. He works as a hairdresser part-time, and part-time at a dry cleaners
 - We have determined this man significant enough risk that he requires a work up....

- But how



Hematuria Investigations

Laboratory Investigations:

1. U/A and culture
 - Leukocytes, Nitrites – Infection
 - R&M – if dysmorphic RBC's +/- Protein = Glomerular cause, crystals stones
 - C&S – Infection

2. Urinary Cytology
 - Sensitivity and Specificity depend on grade of malignancy and number of specimens sampled

3. CBC
 - Hgb - severity of blood loss
 - WBC – infection
 - Platelet loss/coagulopathy

4. Creatinine
 - Renal impairment

5. INR/PTT
 - Coagulopathy

Hematuria Investigations

Radiology Investigations

- Options for Imaging the Urinary Tract
 - Ultrasound
 - CT IVP
 - MRI
 - Intravenous pyelogram

Hematuria Investigations

Radiology Investigations

- Options for Imaging the Urinary Tract

- Ultrasound

- Pro

- Good for renal tumours, stones within the kidney and hydronephrosis
 - Inexpensive
 - Safe

- Con

- Will miss ureteral stones, ureteral tumours and most small or flat bladder tumours, small renal tumours
 - May not differentiate blood clot from tumour in bladder or renal pelvis
 - No functional information

Hematuria Investigations

Radiology Investigations

- Options for Imaging the Urinary Tract

- CT IVP

- Pro

- Most sensitive for detecting any GU pathology
 - Accurate staging of renal/ureteric tumours and renal trauma
 - Non-contrast CT for patients with renal colic
 - May demonstrate other disorders (eg.: abd. aneurysm)

- First choice for patients with gross hematuria**

- Con

- Adverse reaction to IV contrast (allergy and nephrotoxicity)
 - Expensive.
 - Radiation exposure
 - Contraindicated in renal dysfunction, multiple myeloma, contrast allergy, pregnancy

Hematuria Investigations

Radiology Investigations

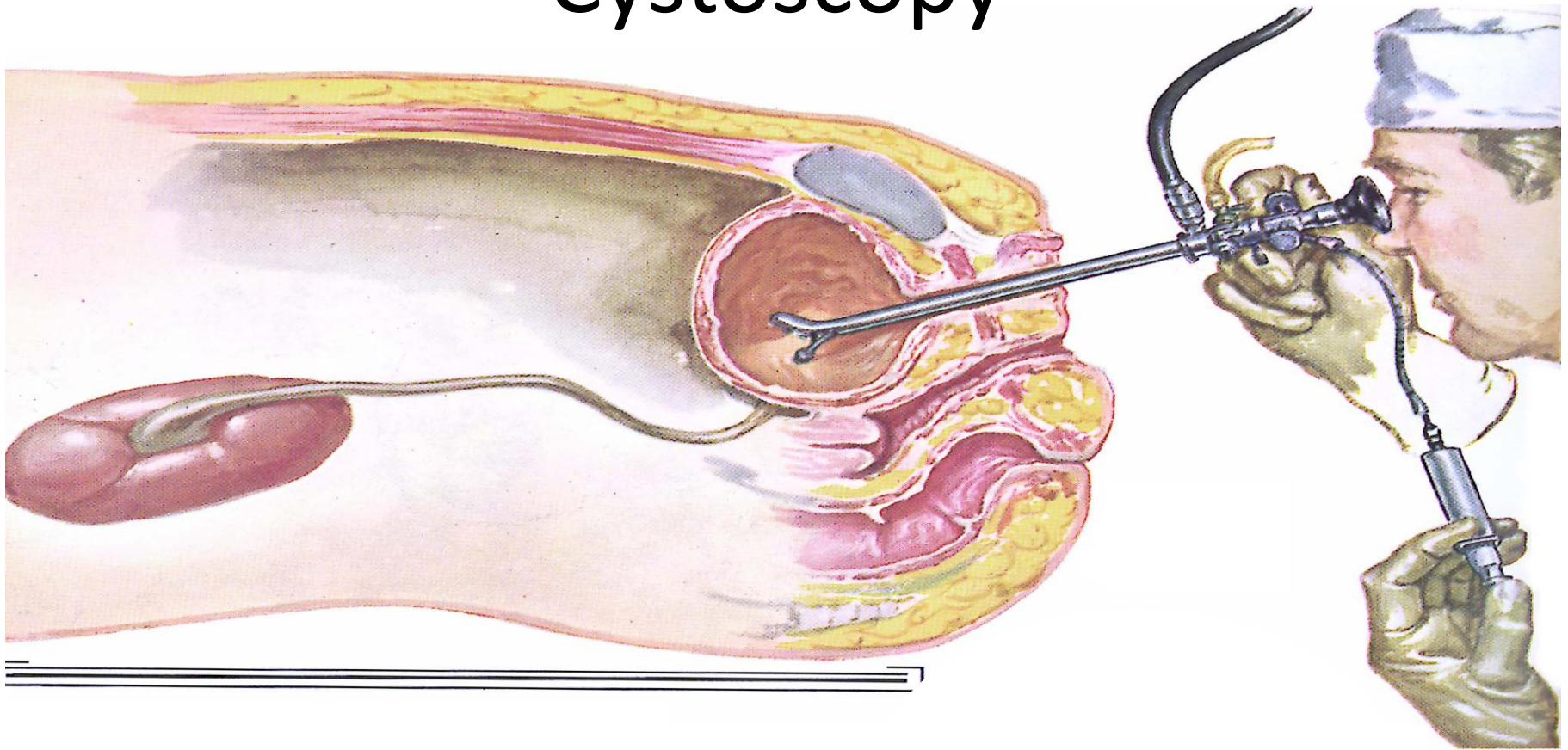
- Painless Gross Hematuria
 - Triphasic CT (CT IVP): arterial/venous/excretory phases
- Microscopic Hematuria
 - Depends on Risk Category (Age > 40 or risk factors)
 - Start with Renal U/S
- Flank Pain
 - Plain film KUB, CT KUB (non con).
- Signs of infection
 - Start with U/S, if findings → may consider CT with contrast

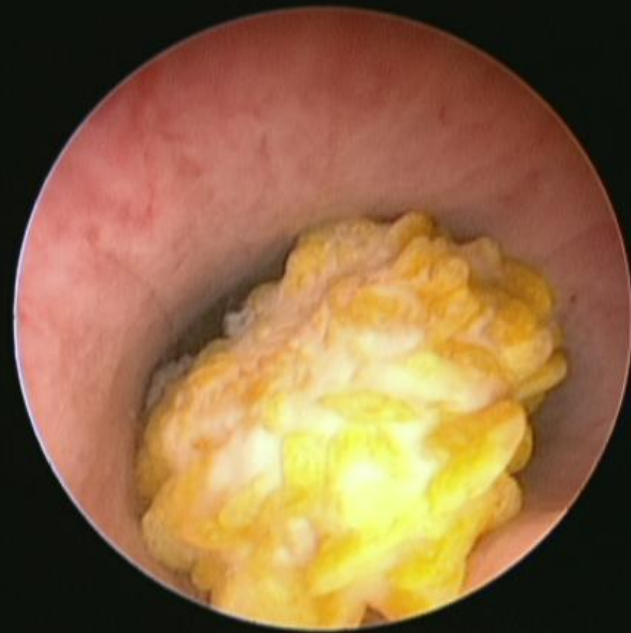
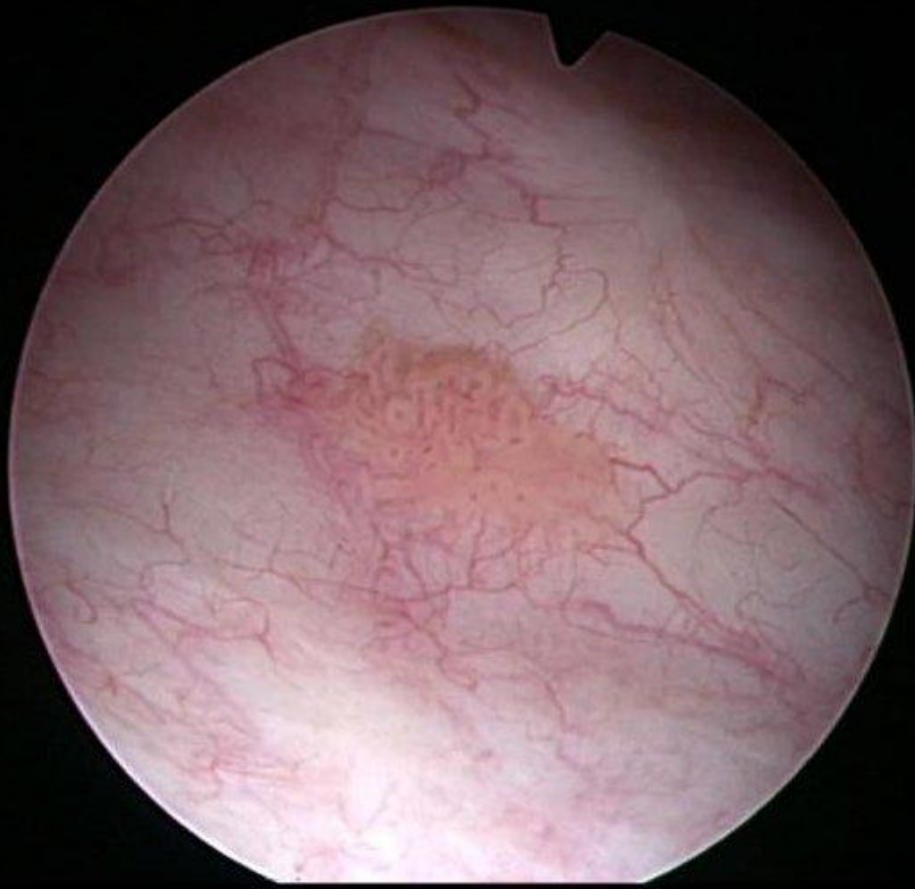Imaging Modality	Pros	Cons
IVP or retrograde pyelogram	<ol style="list-style-type: none"> 1. Suspected stones or urothelial tumors of bladder or ureter. 	<ol style="list-style-type: none"> 1. More expensive. 2. Radiation 3. Not good for renal tumour 4. Contrast: allergies, Nephrotoxic
U/S	<ol style="list-style-type: none"> 1. No ionizing radiation. 2. Inexpensive. 3. Can identify tumor or stone 	<ol style="list-style-type: none"> 1. May miss stones, ureteric & bladder tumors. 2. Unable to differentiate tumors from blood clot.
CT non contrast	<ol style="list-style-type: none"> 1. Used for Renal Colic – best at identifying stones 	<ol style="list-style-type: none"> 1. Ionizing radiation exposure. 2. Risk to fetus in Pregnancy
CT contrast (Triphasic / IVP)	<ol style="list-style-type: none"> 1. Useful identifying abscesses, fluid collections. 2. Ureteric phase – identifies filling defects. 	<ol style="list-style-type: none"> 1. Contrast allergy. 2. Contrast makes visualizing stones difficult if pre-contrast scan not captured

Hematuria Referral

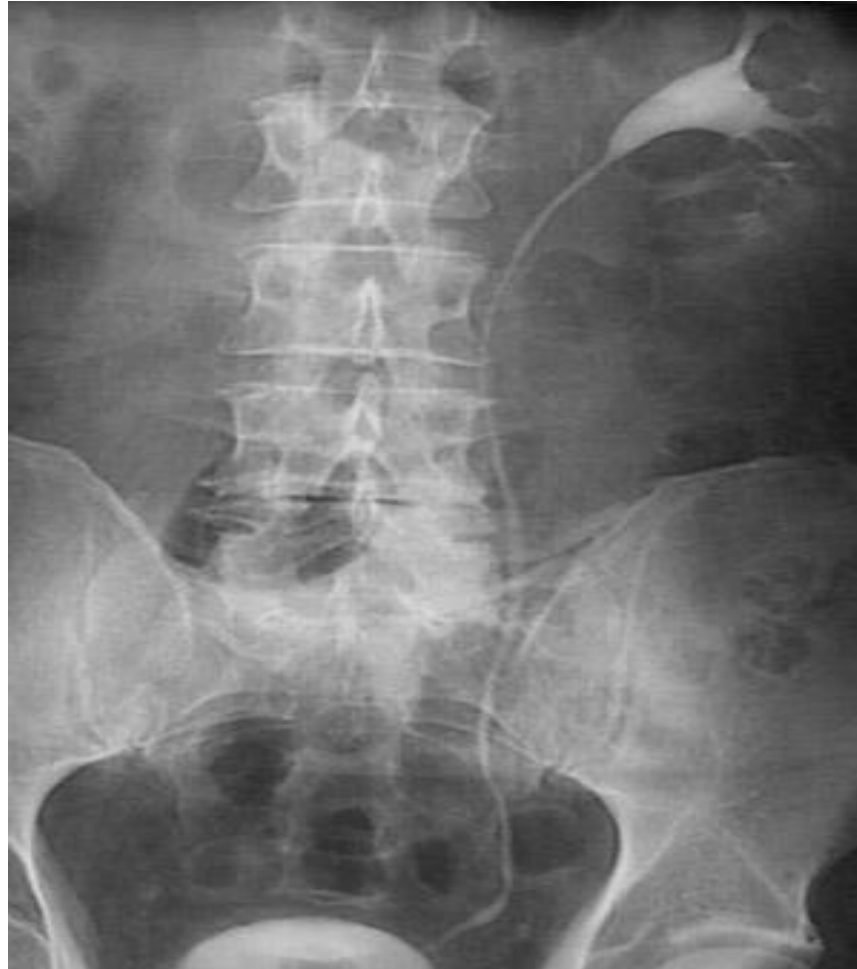- When to refer to Urologist?
 - Any patient with gross hematuria needs both upper tract imaging (radiology) and lower tract imaging (cystoscopy)
- All patients with gross hematuria should be seen by urologist unless obvious cause (i.e. infection)
- What should be done prior to referral?
 - Hx, PE, UA, Urine cytology, Imaging
 - Initial management and stabilization of pt.

Cystoscopy





Retrograde Pyelogram



Hematuria

- Suggested learning resource



Canadian guidelines for the management of asymptomatic hematuria in adults

http://www.cua.org/userfiles/files/guidelines/amh_2008_en.pdf

Hematuria: Acutely Bleeding Patient

- ABC's.
 - Stabilize Pt, Blood products if needed
- Investigations to determine site of bleeding (upper tract vs. lower tract)
 - Treatment based on underlying cause
- Continuous Bladder Irrigation
 - Manually irrigate all clots out of bladder first!
 - Call Urology
- Surgical management
 - Cystoscopy + Fulgaration
 - Intravesical therapies: Alum, formalin, silver nitrate
 - Hyperbaric Oxygen
 - Vascular embolization.
 - Cystectomy and Urinary diversion.



Hematuria Summary

1. Painless Gross Hematuria

- Malignancy until proven otherwise

2. Stones, infections & trauma

- Rarely asymptomatic → History!!!!

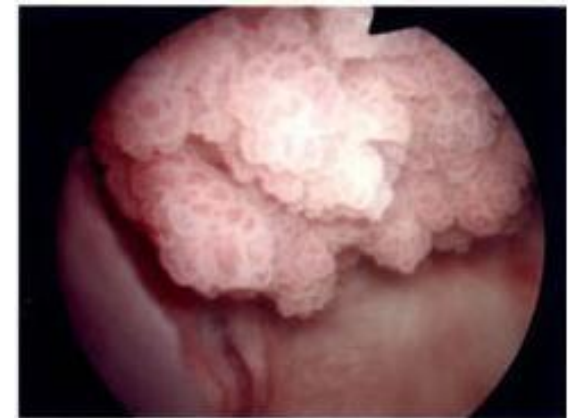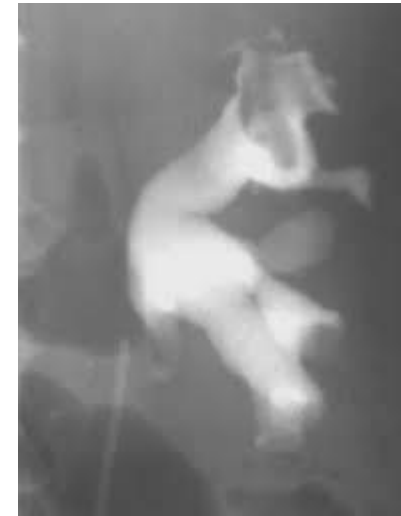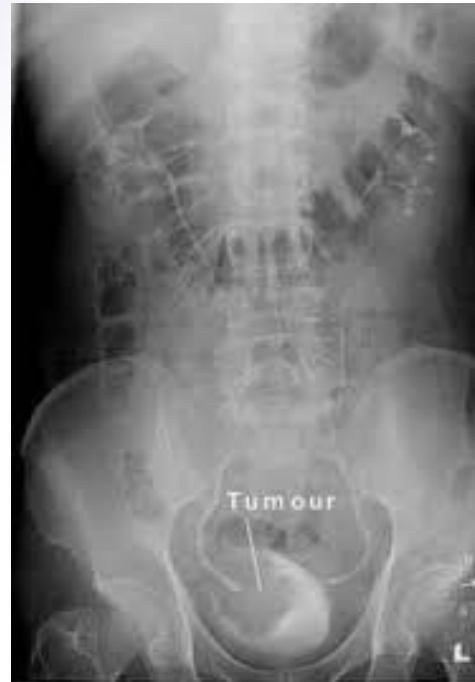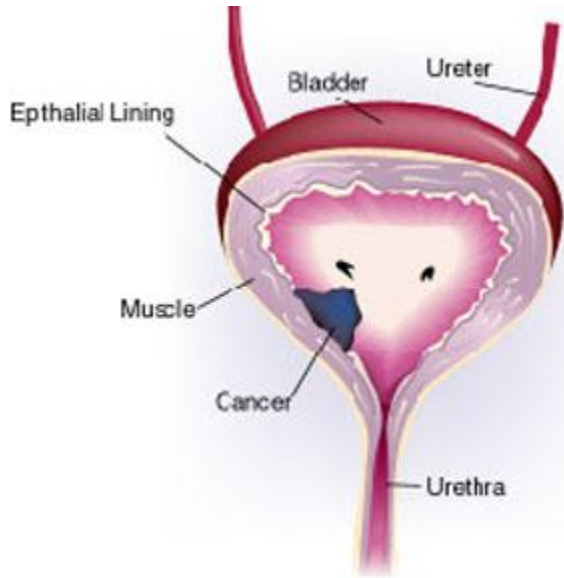
3. Workup

- Hx, PE
- Lab: U/A, Urine C&S, urine cytology, CBC, Cr, INR/PTT
- Imaging: CT or U/S
- Referral to Urologist: gross hematuria, microhematuria with risk factors (See CUA guidelines) or abnormal cytology

4. Management

- Stabilize Pt, +/- CBI, +/- Surgical intervention

Urothelial Carcinoma



Objectives

Urothelial Carcinoma:

1. To provide a framework for you to understand the initial workup and management of patients diagnosed with urothelial malignancies
2. To discuss the classification of urothelial tumours by histological grade and stage, and the implications this has for treatment interventions

Urothelial Carcinoma

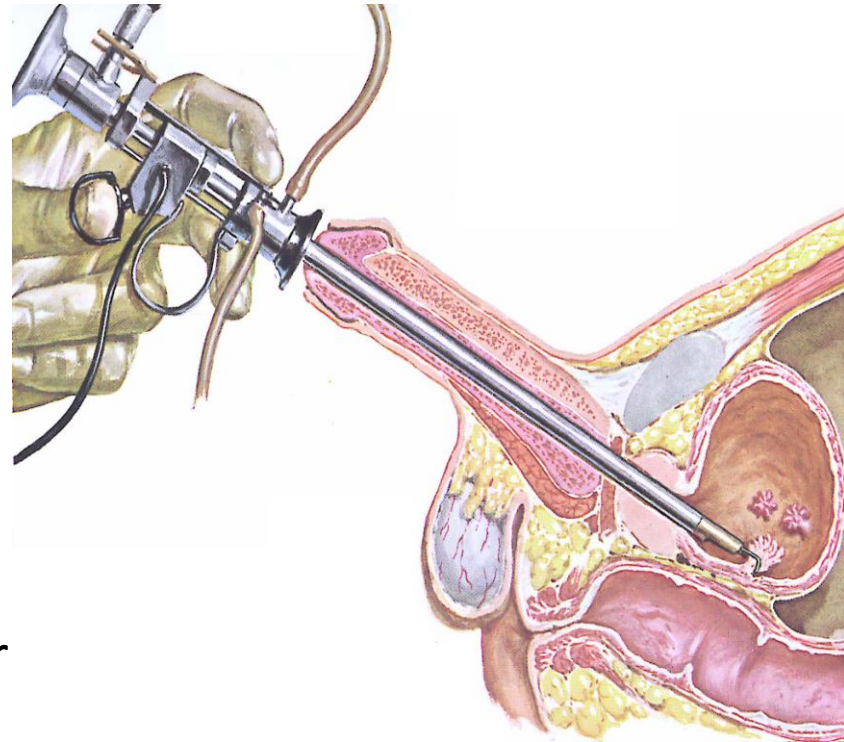
- 65 year old male presents with a 2 day history of gross painless hematuria. He is a long term 2 pack per day smoker. He works as a hairdresser part-time, and part-time at a dry cleaners
 - UA: (+) RBC, (-) nitrites, (-) leuks
 - Urine culture negative
 - Urine cytology shows abnormal cells
 - Renal U/S normal

Next Step....



Urothelial Carcinoma

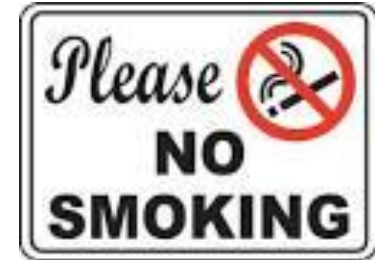- Cystoscopy and CT IVP
 - Recall workup for gross hematuria:
 - Upper tract imaging (Radiology)
 - Lower tract imaging (Cystoscopy)
- Diagnosis
 - Cystoscopy + Biopsy
 - Transurethral resection of lesion and underlying detrusor muscle to stage tumor





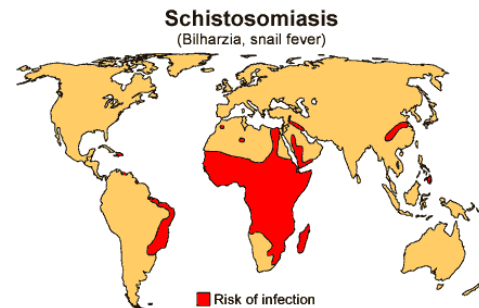
Risk Factors for Urothelial Tumours

- Smoking
- Smoking
- Smoking
- Occupational exposures: Aniline dyes
 - Hairdressers, leather tanners, textile workers, painters, dry cleaners
- Medications
 - Phenacetin – older analgesic, common in australiaasia
 - Cyclophosamide
- Previous radiation exposure
- Chronic cystitis: catheters, infections



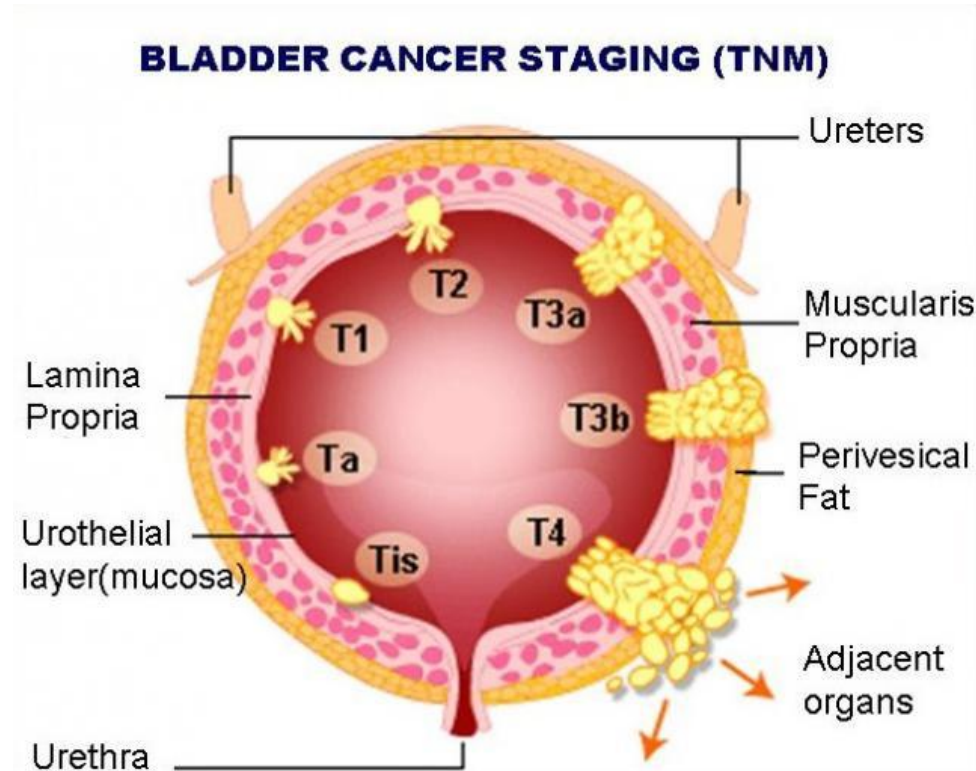
“Bladder Cancer”

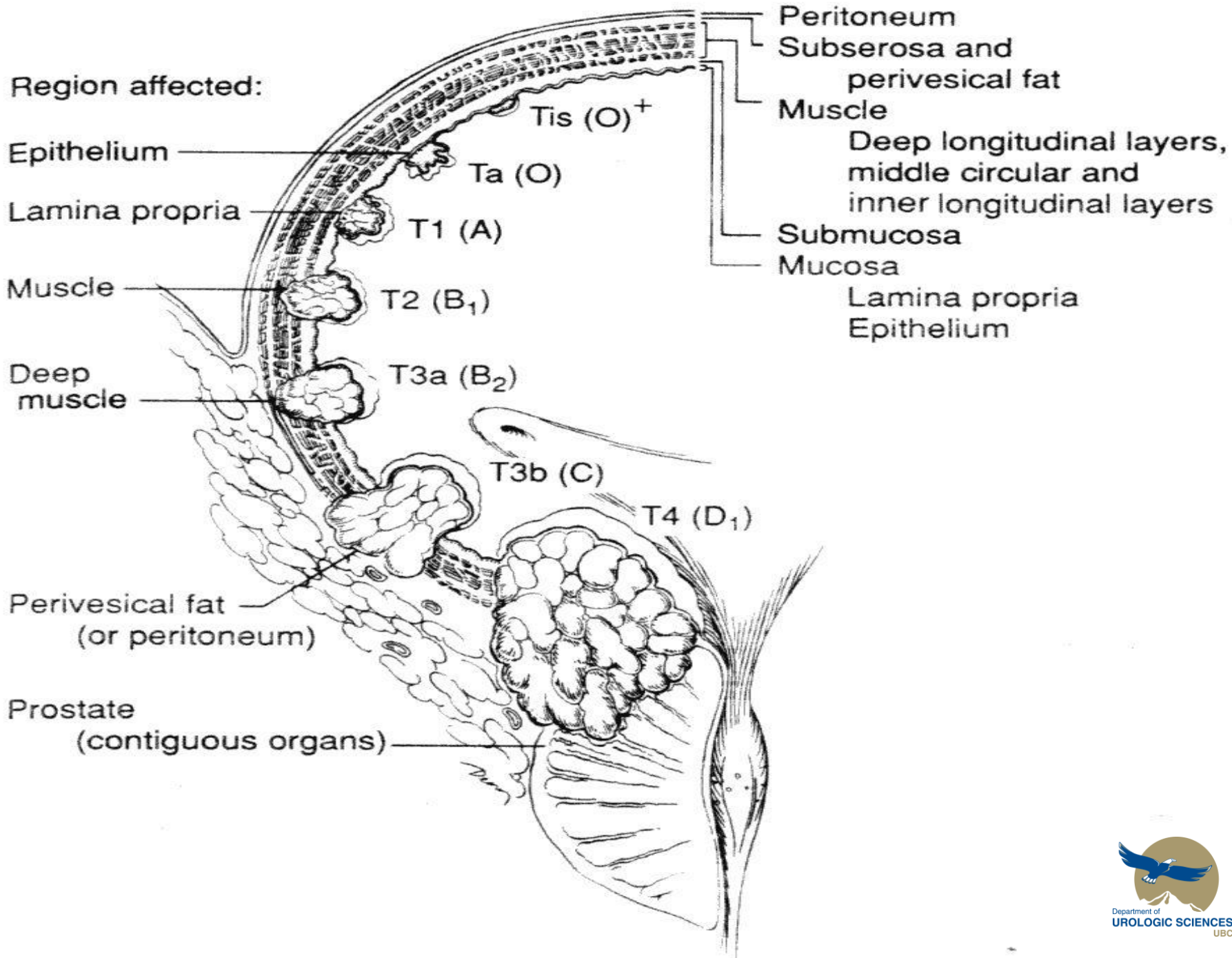
- DDX
 - Urothelial carcinoma (transitional cell carcinoma)
 - Most common!
 - Adenocarcinoma
 - Dome of bladder, associated with Urachus
 - Squamous Cell Carcinoma
 - Associated with chronic inflammation
 - Indwelling catheters
 - bladder stones
 - Schistosomiasis



Urothelial Carcinoma

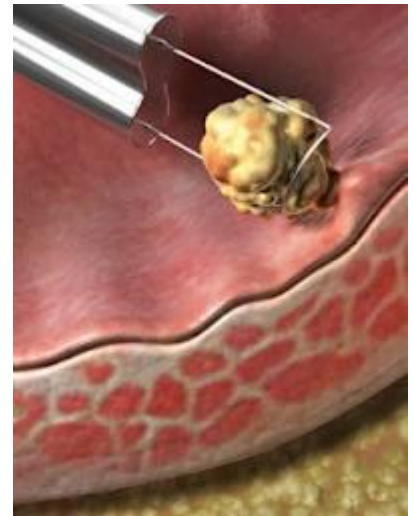
- Grade
 - Histologic appearance
 - Low grade
 - High grade
- Staging
 - Non-Muscle Invasive (NMIBC)
 - Tis, Ta, T1 disease
 - Muscle Invasive (MIBC)
 - >T1 disease





Treatment of Non-Muscle Invasive Disease (NMIBC)

- Transurethral resection of lesion (TURBT)
 - + Strongly consider Mitomycin C to prevent recurrence
- + Intravesical chemotherapy especially if:
 - High grade NMIBC
 - Lamina propria invasion (Stage T1)
 - Carcinoma in-situ (CIS)
 - Multi focal NMIBC tumors
 - Unable to completely resect transurethrally
 - Rapid recurrence after initial resection



Treatment of NMIBC

- Intravesical Chemotherapeutic Agents:
 - Bacille Calmette-Guerin (BCG)
 - Only agent to demonstrate decreased progression
 - Mitomycin
 - Reduces recurrence risk
 - Interferon
 - Doxorubicin
 - Thiotepa

Treatment of NMIBC

- Must reassess response to therapy
 - If:
 - Persistent CIS after intravesical chemotherapy
 - Extensive superficial tumors that cannot be resected

Radical Therapy Required....

Treatment of Muscle Invasive Bladder Cancer

- Radical Cystectomy
 - +/- Systemic chemotherapy
- If palliative, may still require cystectomy if uncontrollable hematuria (requiring transfusions etc)

Treatment of Muscle Invasive Bladder Cancer

- Indications for Radical Cystectomy
 - Muscle Invasive Disease ($\geq T2$)
 - CIS / High grade NMIBC that fails intravesical therapy
 - Extensive NMIBC that cannot be resected
 - Palliation to control hemorrhage

Radical Cystectomy + Urinary Diversion

- Once Bladder is removed...

Where does the urine go???

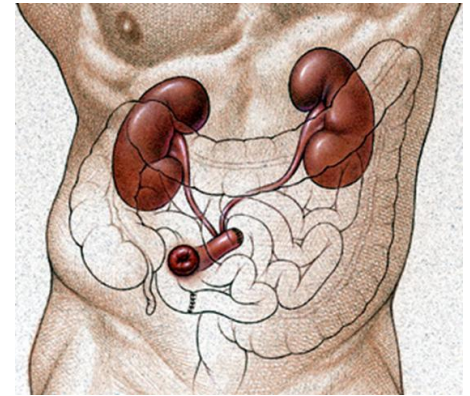
- Urinary diversion is needed

- Ileal Conduit

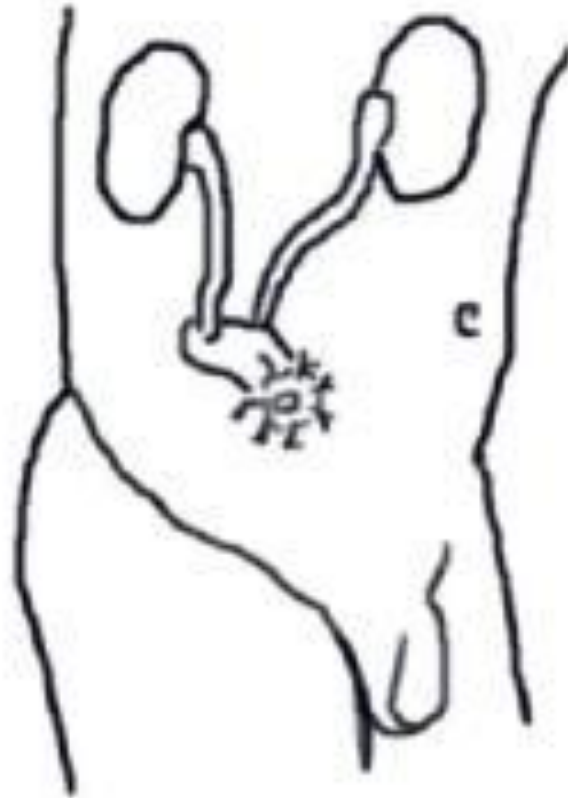
- Pros – simple, least complications
- Cons – abdominal stoma, no continence

- Neobladder

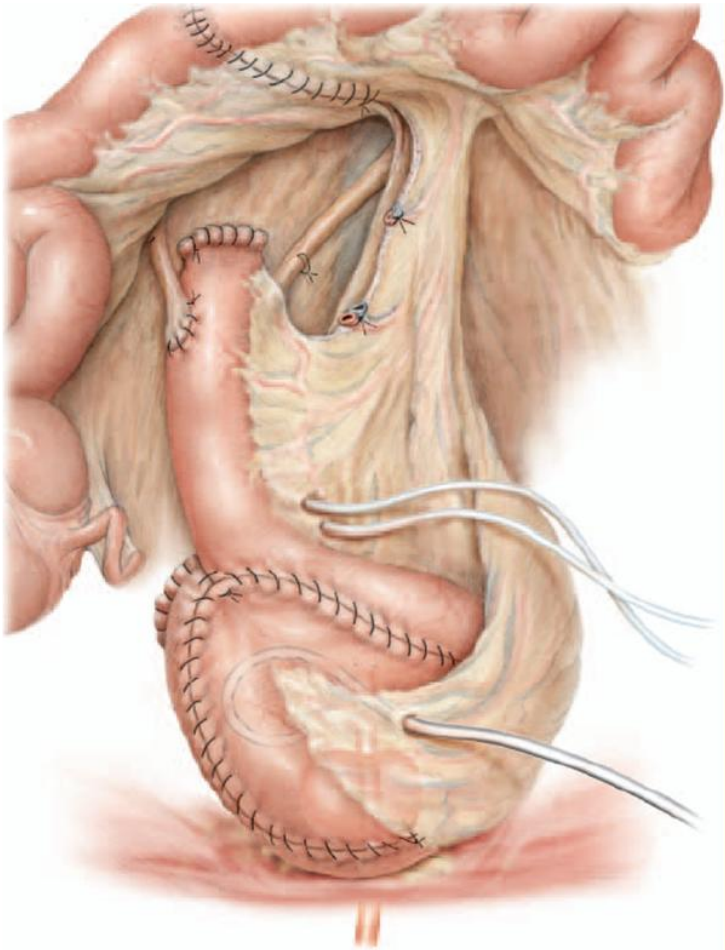
- Pros – continent with use of catheters
- Cons – Increased surgical complications, increased risk of metabolic derangements



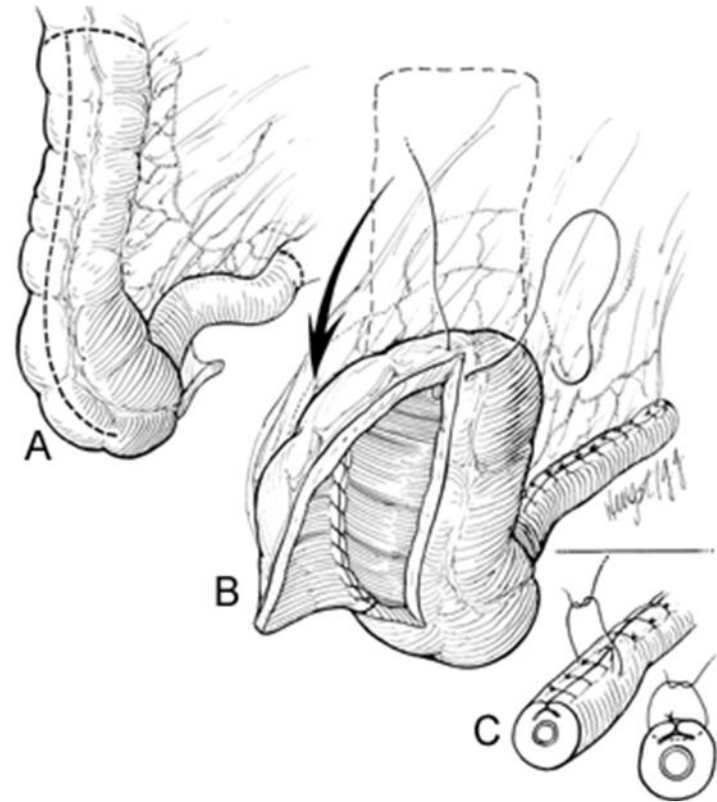
Ileal Conduit



Neobladders



Orthotopic



Heterotopic

Chemotherapy for Urothelial Carcinoma

- Gemcitabine / Cisplatin most common
- MVAC (methotrexate / vinblastine / adriamycin / cisplatin)
- 5% Survival benefit at 5 years if given neoadjuvant
- Adjuvant benefit less clear

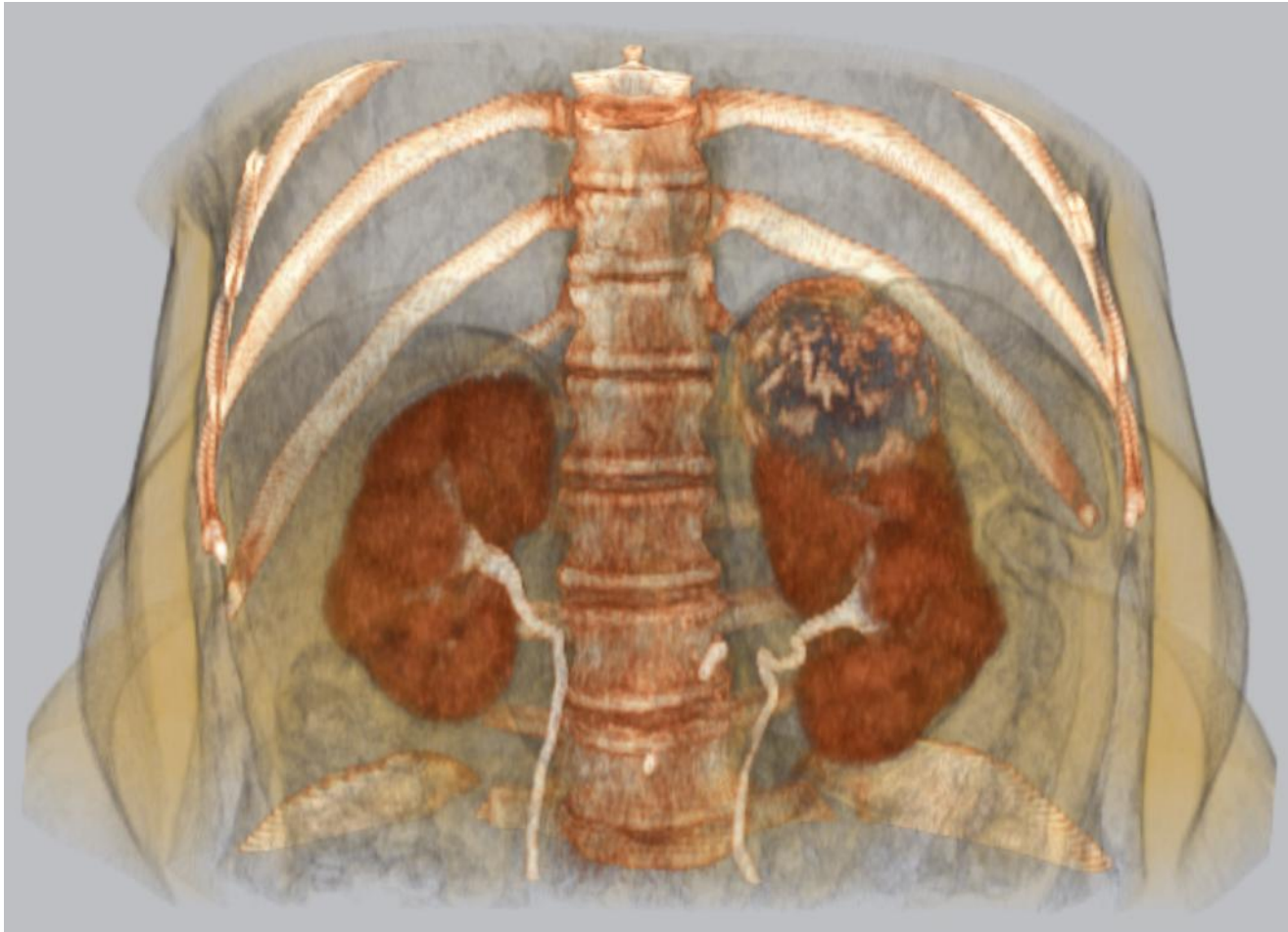


Objectives

Urothelial Carcinoma:

1. To provide a framework for you to understand the initial workup and management of patients diagnosed with urothelial malignancies
2. To discuss the classification of urothelial tumours by histological grade and stage, and the implications this has for treatment interventions

Renal Mass



Objectives

Renal Mass

1. Give a differential diagnosis for a solid mass in the kidney
2. Describe the evaluation of a patient with a suspected renal cell carcinoma
3. Give three indications for a partial nephrectomy rather than a radical nephrectomy for renal cell carcinoma

Renal Mass

- 65 year old male presents with a 2 day history of gross painless hematuria. He said he had some vague flank pain a few weeks ago. He has never smoked, and works as an accountant
 - UA: (+) RBC, (-) nitrites, (-) leuks
 - Urine culture negative
 - Urine cytology normal
 - Ultrasound showed a mass in left kidney

Next Step....

Renal Mass



- Presentation:
 - Typically incidental finding!
 - Classic Triad:
 - Flank pain, hematuria, palpable mass (uncommon)
- How do you ‘work-up’ a Renal mass?

Need to think about your differential diagnosis...

Renal Mass

Renal Mass (U/S or CT)

Benign

- Oncocytoma
- Angiomyolipoma
- Abscess
- Psuedotumour
 - Dromedary Hump
 - Hypertrophied column of Bertin
 - Compensatory Hypertrophy

Malignant

- Renal Cell Carcinoma
- Urothelial Cell Carcinoma
- Metastasis
 - Lymphoma/leukemia
 - Lung
 - Breast
- Wilms Tumour (peds)

Renal Mass Investigations

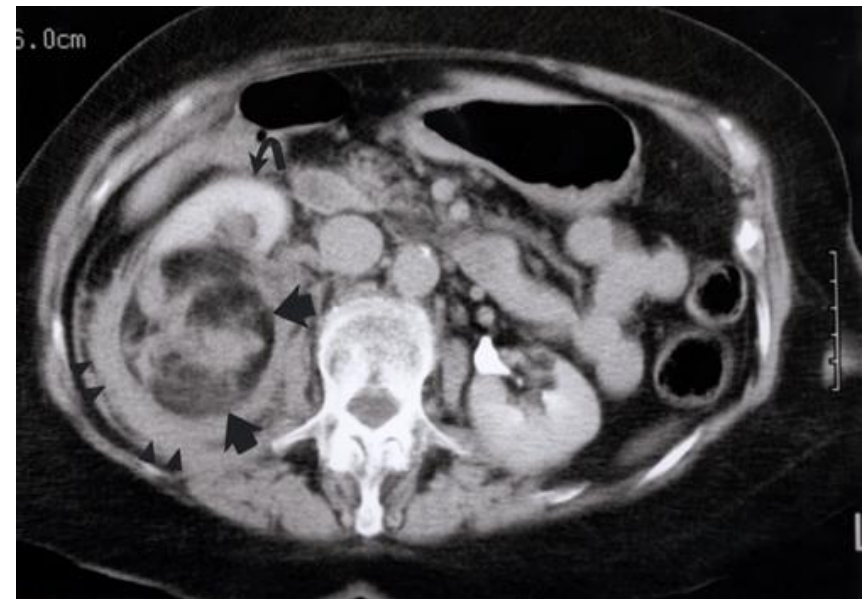- Imaging
 - CT Abdo pelvis + contrast
 - Characterize mass
 - Assess for tumor extension
 - IVC thrombus
 - Nodes
 - Mets
 - Contralateral renal abnormalities
 - CXR
 - Assess for metastasis
- Laboratory
 - Alk Phos (bone metastasis)
 - Liver function testing → hepatic mets / portal vein involvement
 - Calcium
- Biopsy?
 - Typically recommended only when diagnosis is unclear.

Why Investigate Calcium?

- Bone Mets or Paraneoplastic syndrome!
 - 20-30% of RCC have Paraneoplastic Syndrome
 - Increased ESR
 - Wt loss, cachexia
 - Fever
 - Anemia
 - Hypertension (Due to increased Renin)
 - Hypercalcemia (PTH-like Substance)
 - Increased AlkPhos
 - Polycythemia (increased EPO production)
 - Stauffer's syndrome – abnormal liver enzymes - reversible

Benign Renal Masses

- Angiomyolipoma (AML)
 - Fat in a mass
 - (-10 to -100 HU) is diagnostic of AML
 - Composed of:
 - Fat
 - Smooth Muscle
 - Blood Vessels
 - Risk of hemorrhage near 50% once size >4cm

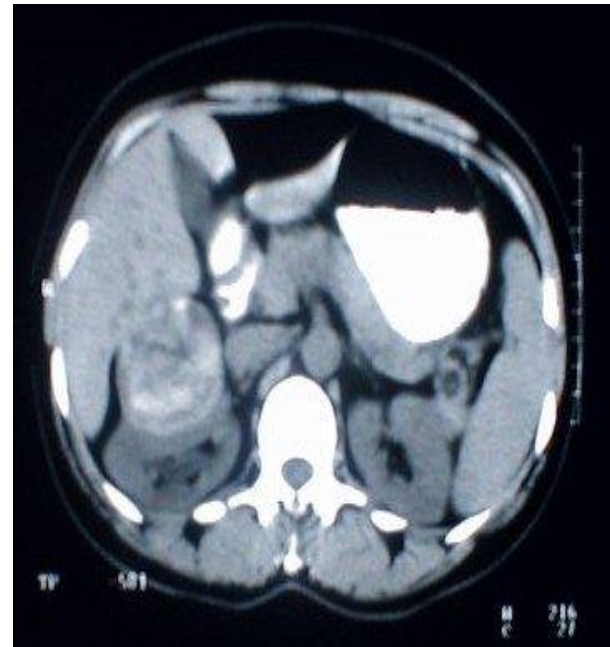

Benign Tumors

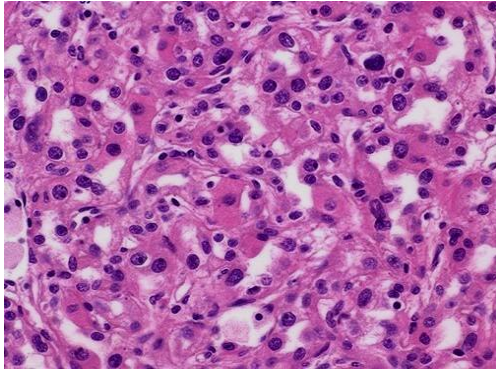
- Know that they exist.
- DDX:
 - Oncocytoma
 - angiomyolipoma (1-2% malignant)
 - papillary adenoma
 - pseudotumors etc....
- Differentiating pseudotumors from real tumors.
 - DMSA scan
 - Pseudotumors will have normal uptake, tumors will be decreased

Malignant Renal Cell Carcinoma

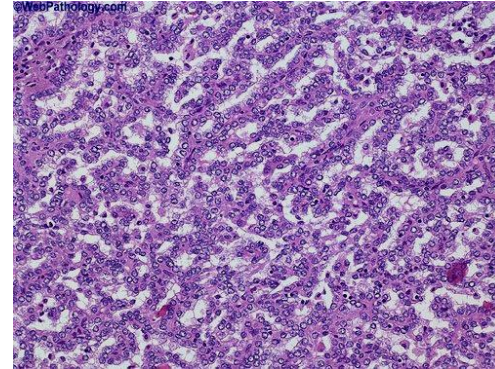
- Accounts for 90% of solid renal masses.
- Several different subtypes
 - Clear Cell RCC is most common
- 25% present with Mets



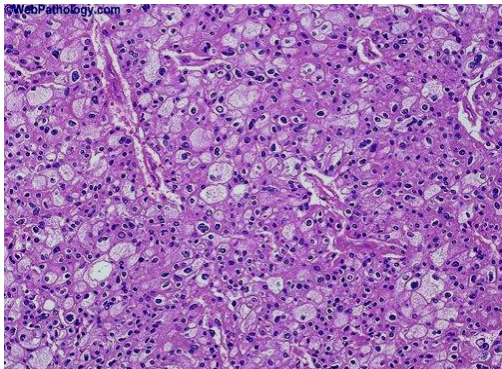
Renal Cell Carcinoma Histology



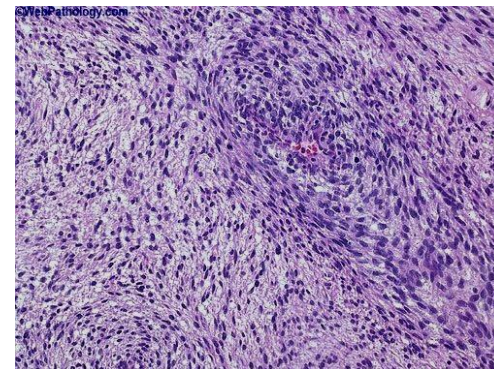
Clear cell 75-80%



Papillary 7-14%



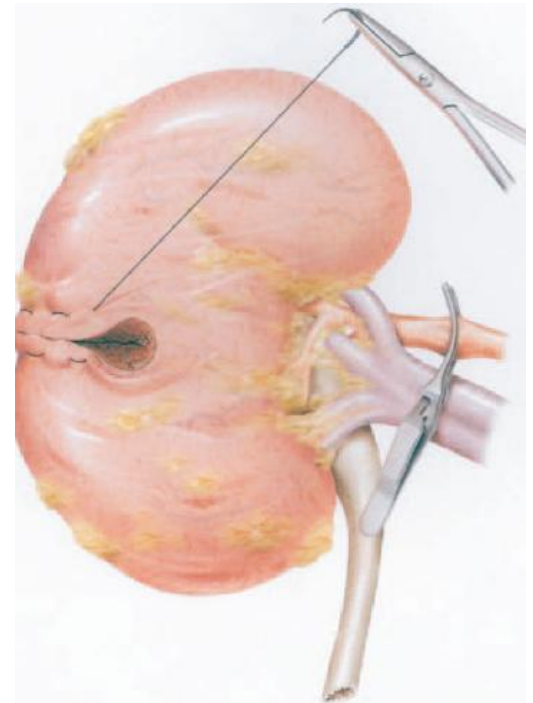
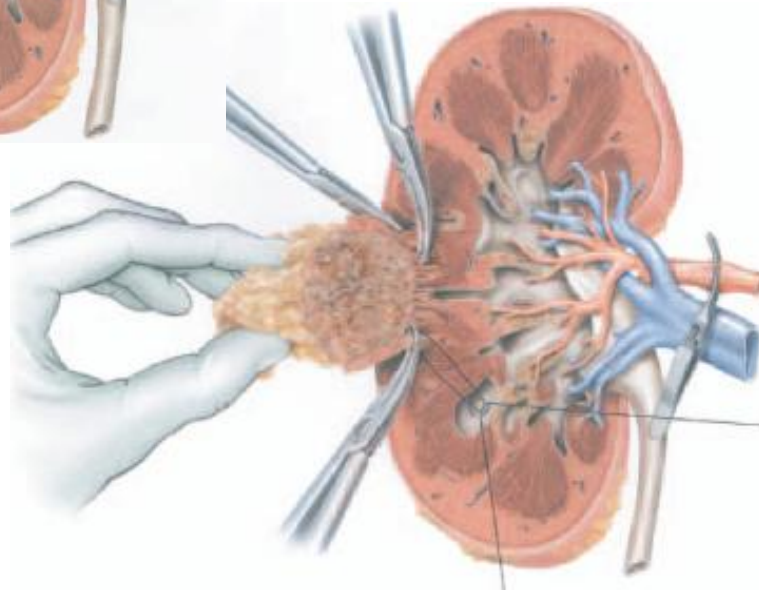
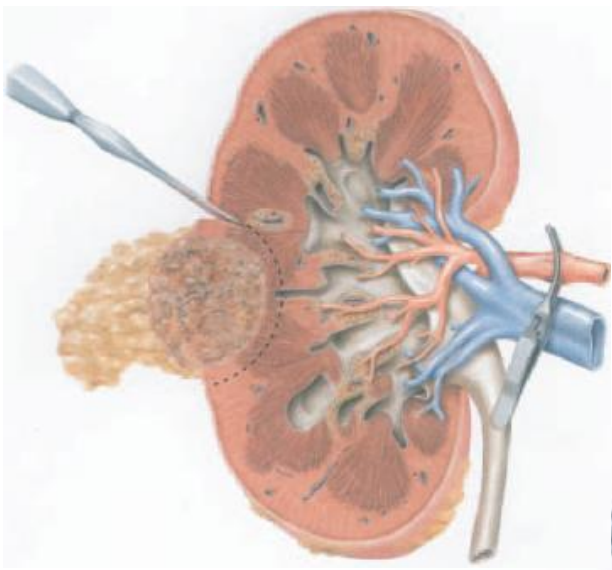
Chromophobe 5-8%



Sarcomatoid / Others 1-2%

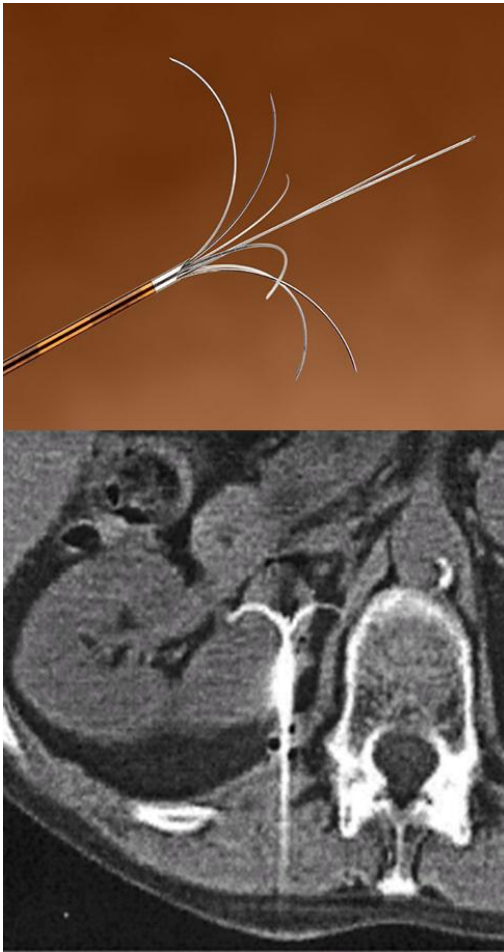
Renal Cell Carcinoma

- Treatment
 - Locally confined mass
 - Nephrectomy
 - Partial Nephrectomy
 - Indications for partial nephrectomy
 - » Small tumor <7cm amenable to partial nephrectomy
 - » Solitary kidney or significant renal impairment
 - » Bilateral tumors
 - » Hereditary Syndromes
 - Von Hippel-Lindau Syndrome
 - Metastatic RCC
 - Combination of Nephrectomy + Chemo (Sunitinib)

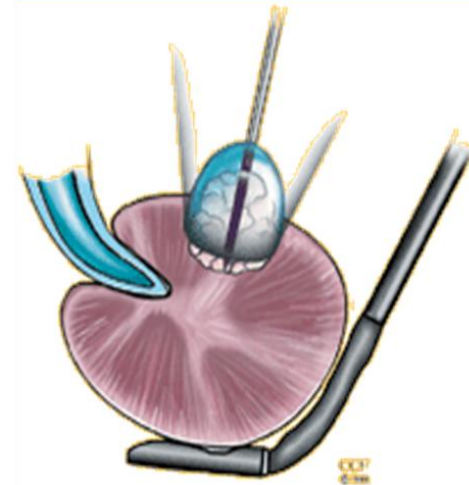
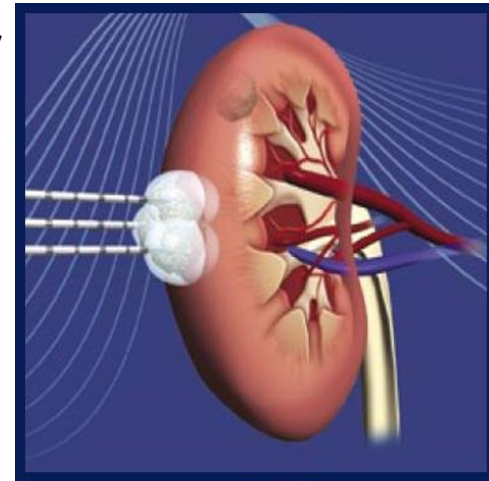


Ablation Therapies

RFA



Cryotherapy



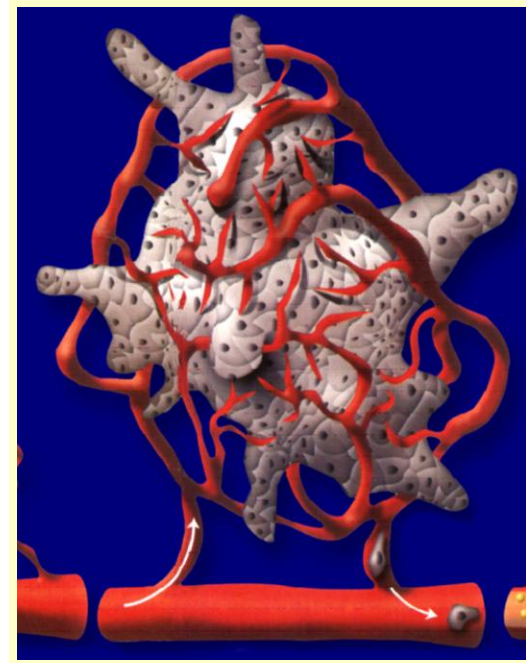
Renal Cell Carcinoma

Five year disease-specific survival
(following most effective treatment)

T		
	T1	95%
	T2	90%
	T3a	60%
	T3b, c	25% (following complete removal of IVC thrombus)
	T4	20%
N		
	N1, 2	10% – 20%
M		
	M1	0%

Targeted Therapy

- Tyrosine kinase (esp. VEGFR) inhibitors:
 - sunitinib
 - sorafenib
 - pazopanib
 - axitinib
- Anti-VEGF-mAb:
 - bevacizumab
- mTOR inhibitors:
 - temsirolimus
 - everolimus



Other Malignant Renal Tumors

- Renal Urothelial Cell Carcinoma / “Upper Tract TCC”
 - Because transitional cells line renal pelvis, ureters & bladder, must perform nephroureterectomy
- Wilm’s Tumor
 - Pediatric tumour
- Sarcoma
- Metastasis to Kidney
 - Leukemia, lymphoma
 - Lung
 - Breast





Objectives

Renal Mass

1. Give a differential diagnosis for a solid mass in the kidney
2. Describe the evaluation of a patient with a suspected renal cell carcinoma
3. Give three indications for a partial nephrectomy rather than a radical nephrectomy for renal cell carcinoma

Renal Mass

- Learning Resources

- Canadian Consensus: Management of kidney cancer: Canadian kidney cancer forum 2008 Consensus statement

<https://www.kidneycancer canada.ca/media/files/81.pdf>

- Canadian Consensus: Management of advanced kidney cancer: Canadian kidney cancer forum 2013 Consensus Update

<https://www.kidneycancer canada.ca/media/886673/KCRNC%20mRCC%20Consensus%202013%20CUAJ%202013.pdf>

Stones



Renal Colic

Objectives

1. Give a differential diagnosis for acute flank pain including two life-threatening conditions
2. Describe the laboratory and radiologic evaluation of a patient with renal colic
3. Know 4 different kinds of kidney stones and the risk factors for stone formation
4. Know 3 indications for emergency drainage of an obstructed kidney

Renal Colic

- 65 year old male presents with a 2 day history of gross hematuria with significant left sided flank pain. He has never smoked, and works as an accountant
 - UA: (+) RBC, (-) nitrites, (+) leuks
 - Urine culture negative

Next Step....

Renal Colic DDX

- Life Threatening:
 - Abdominal Aortic Dissection
 - Abdominal Aortic Aneurysm Rupture
 - Appendicitis
 - Ectopic Pregnancy
 - Septic Stone
- GI
 - Cholecystitis
 - Biliary Colic
 - Acute Pancreatitis
 - Diverticulitis
 - Duodenal Ulcer
 - Inflammatory Bowel Disease
 - Viral gastritis
 - Splenic Infarct
- Gyne
 - Pelvic inflammatory Disease
 - Ovarian Torsion/Rupture
 - Endometriosis
- GU
 - Renal/Ureteric Calculi
 - Renal Abscess
 - Pyelonephritis
 - Renal Vein Thrombosis
 - Acute Glomerulonephritis
- Other
 - Acute lumbar disc herniation
 - Herpes Zoster
 - Fitz-Hugh-Curtis Syndrome



“Wait a minute here, Mr. Crumbley. ...
Maybe it isn't kidney stones after all.”

Renal Colic Investigations

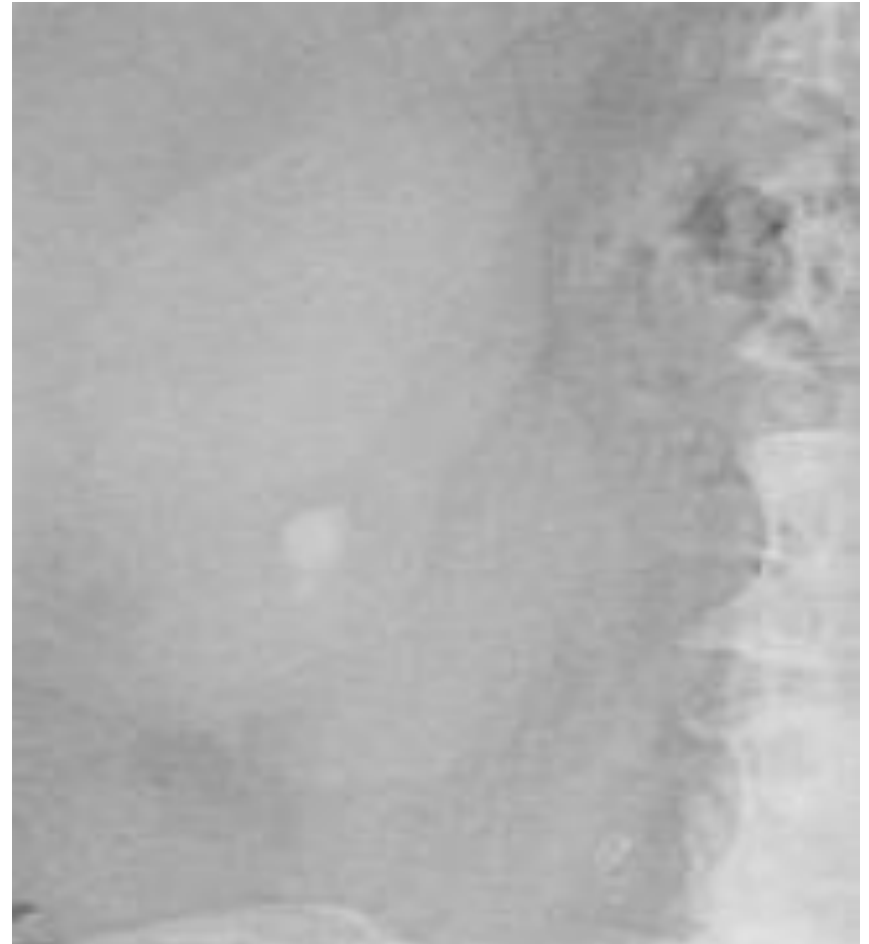
What investigations would you like to order....

Acute Renal Colic Investigations

- CBC
 - WBC – increased indicates inflammation or infection
- Creatinine
 - Assess for impaired renal function (obstruction)
- Urine Microscopy
 - Bacteriuria, pyuria, pH

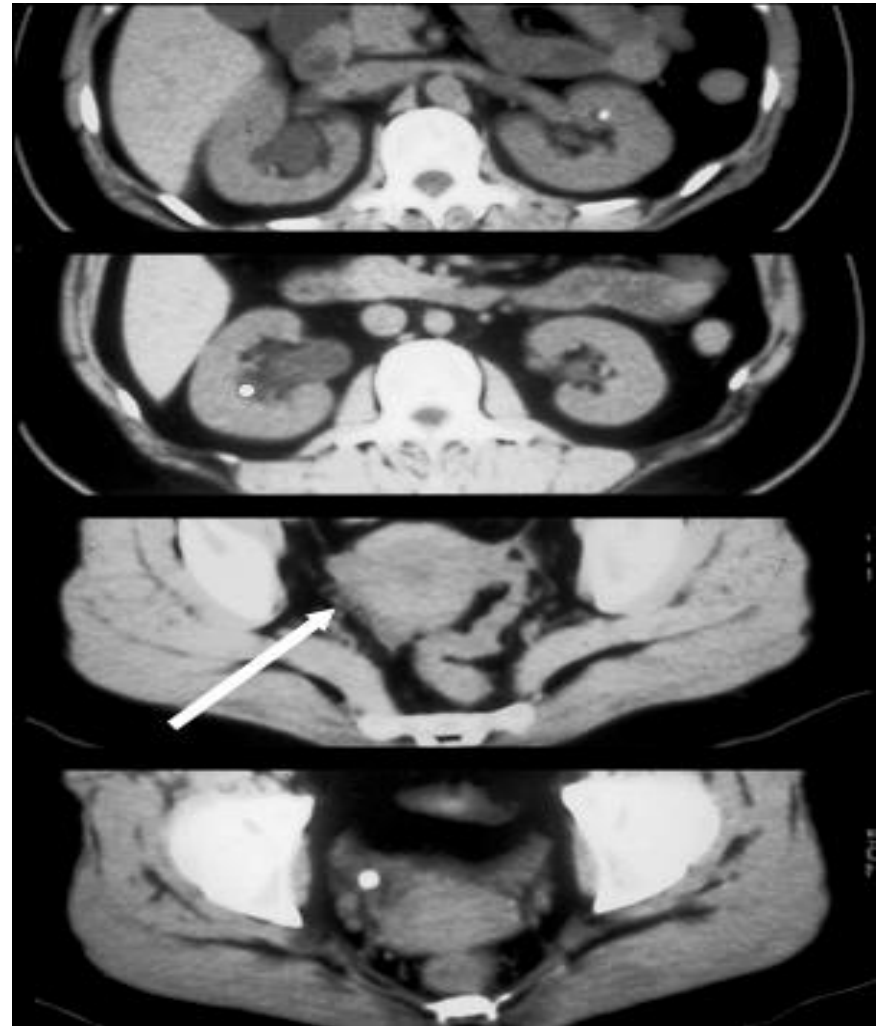
Renal Colic – 1st Imaging Test

- Plain Film KUB!
 - ~85% of stones are Radio-opaque on plain film.
 - No info on degree of obstruction though.



Renal Colic – Radiologic Evaluation

- CT Scan, hold the contrast
 - **CT-KUB.**
 - Fast Inexpensive
 - Imaging choice in most emergency rooms
- Degree of obstruction inferred by presence of hydronephrosis



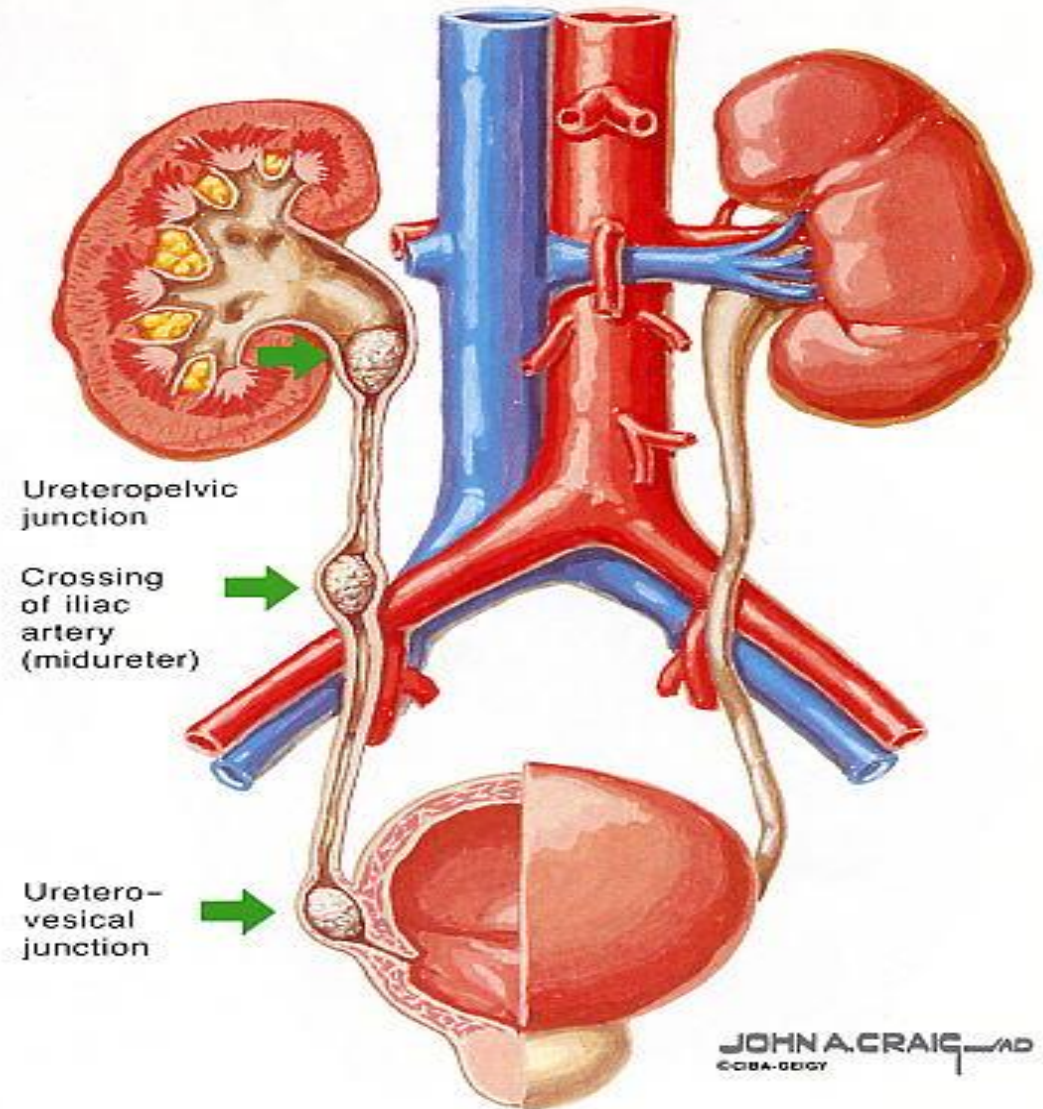
Stones - Factoids

- They are common!
 - Lifetime risk in North American Male is 1 in 8
 - M:F ratio is 3:1
- Presenting complaint
 - Renal colic caused by acute obstruction of ureter by stone
- Initial Evaluation
 - Focuses on excluding other potential causes of abdominal or flank pain
- Non-obstructing stones
 - Should not cause pain unless they are associated with Urinary tract infection

Ureteric Stones

- 3 Common sites of impaction or obstruction

(3 sites of physiologic narrowing)



Ureteric Stones

- Spontaneous passage?

Size	Likelihood
4mm or less	90%
5-7mm	50%
8mm or larger	20%

- Pharmacologic aid in spontaneous passage?
 - Alpha blockers: Tamsulosin

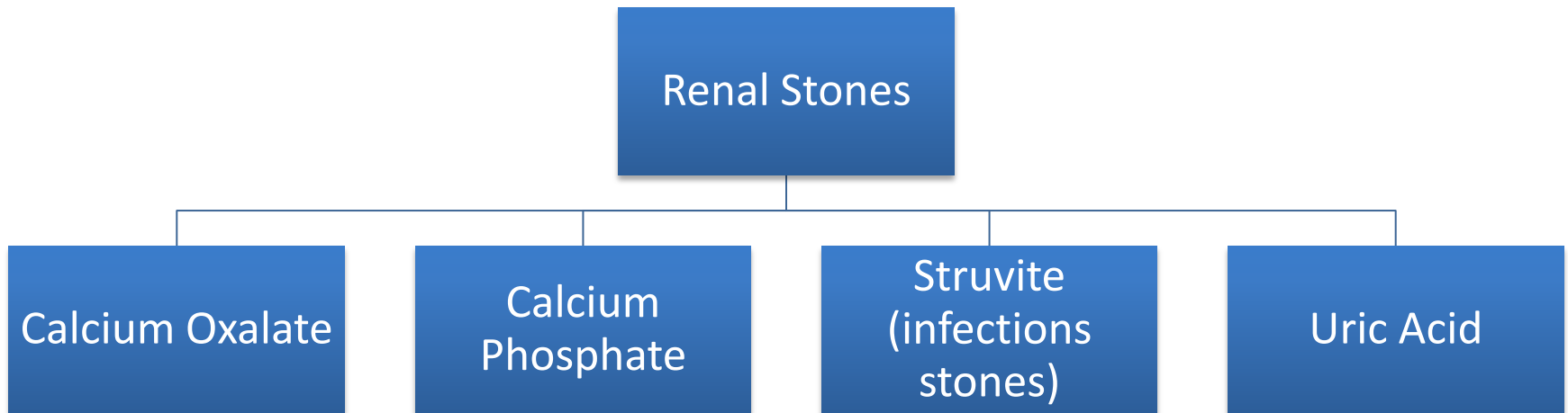
Renal and Ureteric Stones

- So you have established that there is a stone
 - When is ‘immediate’ referral to a urologist necessary?

Immediate Referral to Urology

- Obstructed ureter with
 - Fevers/chills, bacteriuria or elevated WBC
 - = Risk of Urosepsis = emergency
- Obstructed Ureter with
 - Insulin dependent DM
 - Risk of papillary necrosis or emphysematous pyelonephritis
- Solitary Kidney
- Renal failure
- Significant co-morbid conditions
 - i.e. CHF, pregnancy etc.

Common Types of Stones



Calcium Oxalate

- Most common type of stones
- Risk Factors:
 - Dietary Hyperoxaluria: chocolate, nuts, tea, strawberries, peanut butter, cabbage or excessive restriction of dietary calcium.
 - Hypercalciuria
 - Inherited increased absorption
 - Hyperparathyroidism
 - Dietary Hypercalciuria
 - Sodium and Protein

Calcium Phosphate


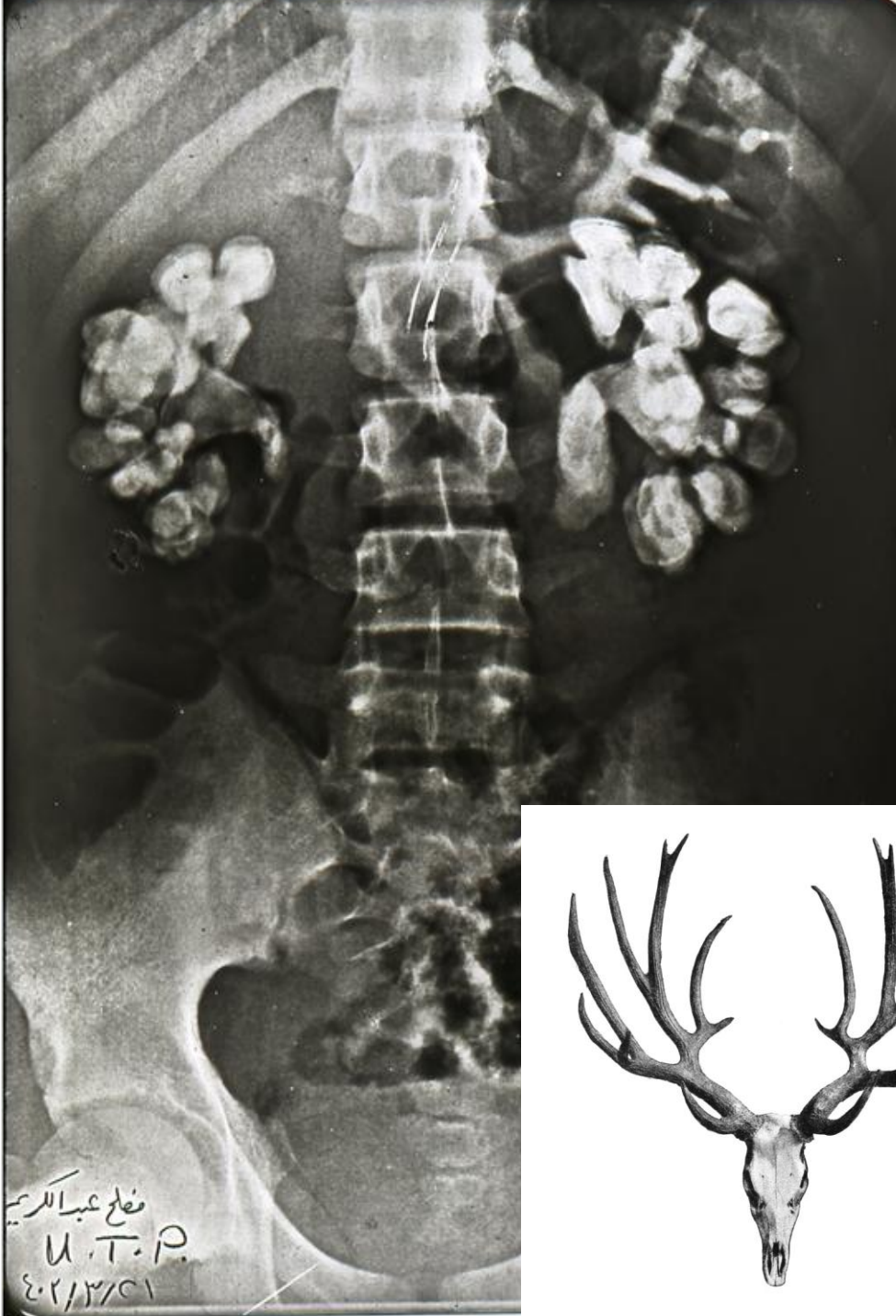
- Second most common stone type
- Often seen in patients with metabolic abnormalities:
 - Primary Hyperparathyroidism
 - Distal Renal tubular acidosis.
 - Hypercalcemia due to Malignancy or Sarcoidosis

Uric Acid

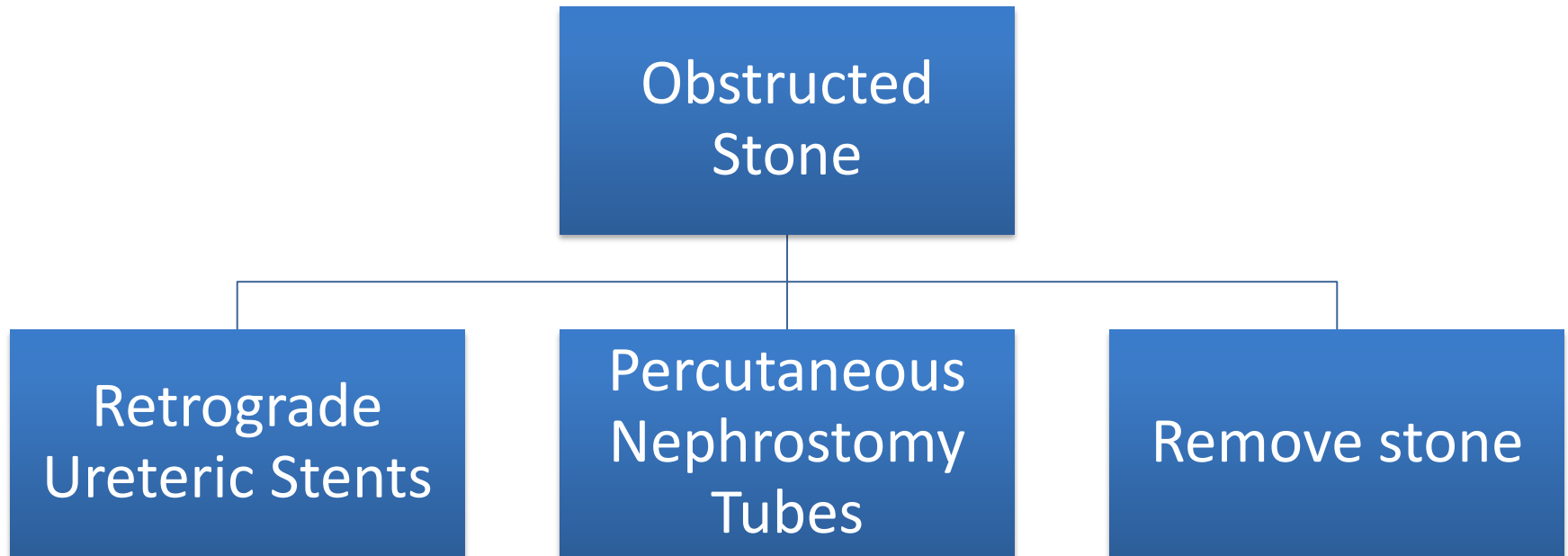
- Radiolucent on Plain X-Rays, but is visualized on CT scan
- Risk Factors:
 - Persistent Acidic urine:
 - Low urine volumes
 - Chronic diarrhea
 - Excessive sweating
 - Inadequate fluid intake
 - Gout (Hyperuricemia)
 - Excess dietary purine (Meat)
 - Chemotherapy for lymphoma, leukemia

Struvite (Infection Stones)

- Composed of MAP
 - Magnesium + Ammonium Phosphate & Calcium
- Can only form if urine pH >8.0!
 - Thus: usually only in presence of urease +ve bacteria
 - Proteus, Klebsiella, Providentia, Pseudomonas, Staph Aureus
 - Note: E Coli does NOT produce urease
- Tend to form Staghorn stones

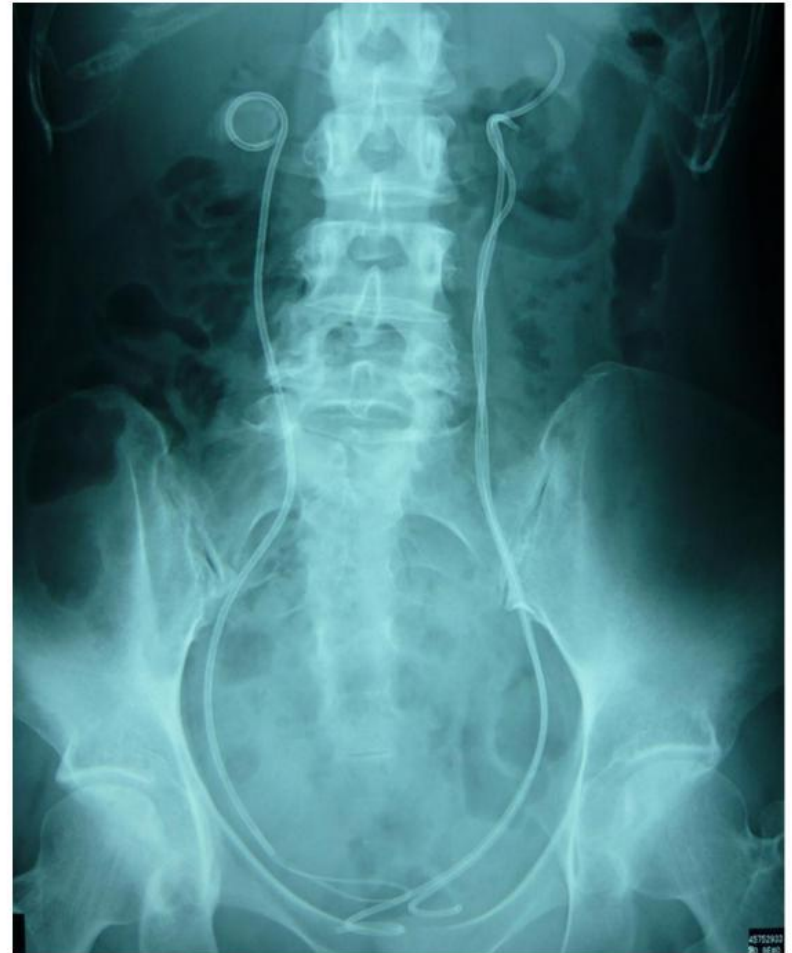

Relieving Obstruction



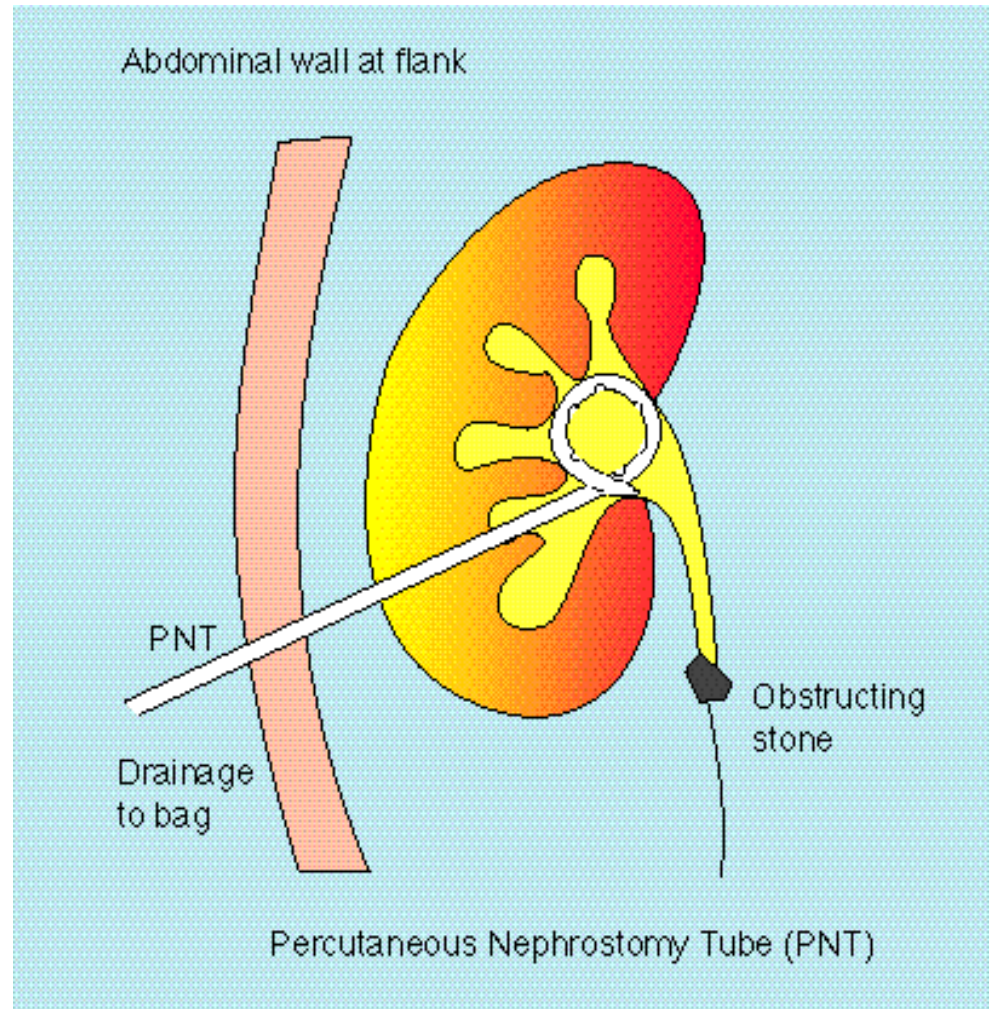
Ureteric Stents

- “Double J Stents”
 - Stay in place b/c of curled ends
 - Can place these Antegrade or Retrograde
 - Typically requires General Anesthetic
 - Low risk of bleeding



Percutaneous Nephrostomy Tubes

- “Neph Tubes”
 - Placed under **local anesthetic** by Interventional Radiology
 - **Increased Risk of Bleeding**



Treating/Removing Stones

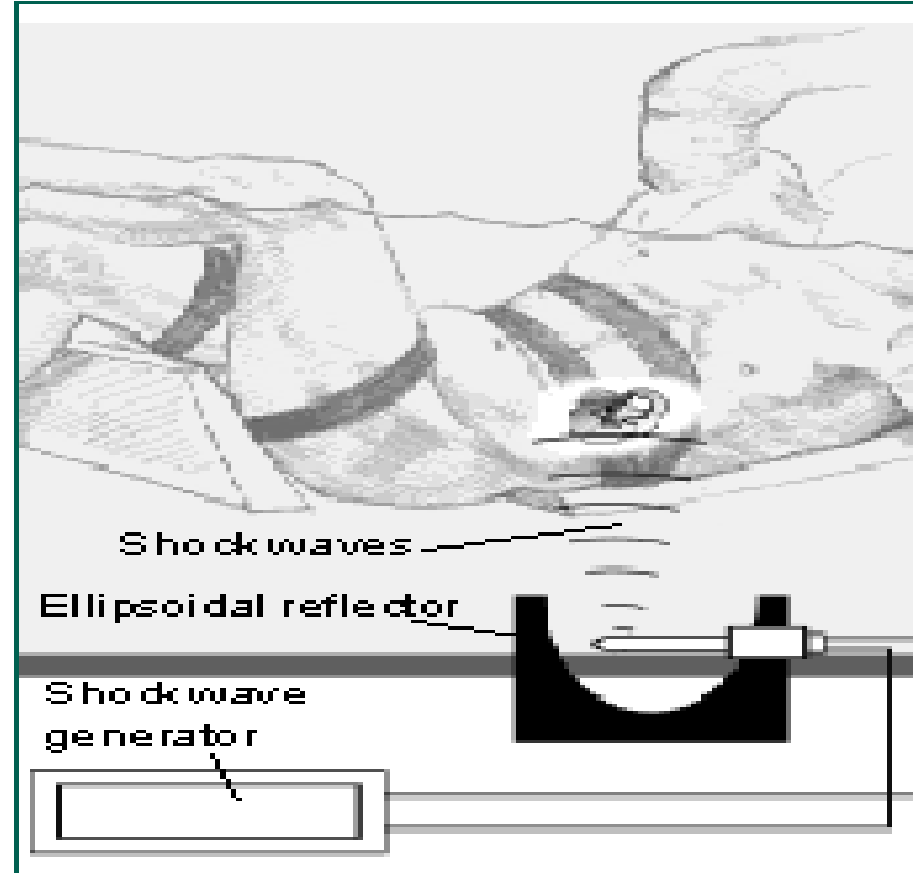
- Ways to Treat stones
 - Conservative passage + Alpha Blocker (Flomax) + Hydration + NSAID (if Normal GFR)
 - Extracorporeal Shockwave Lithotripsy (ESWL)
 - Ureteroscopy + Basket or Laser
 - Percutaneous Nephrolithotomy

Treating Stones

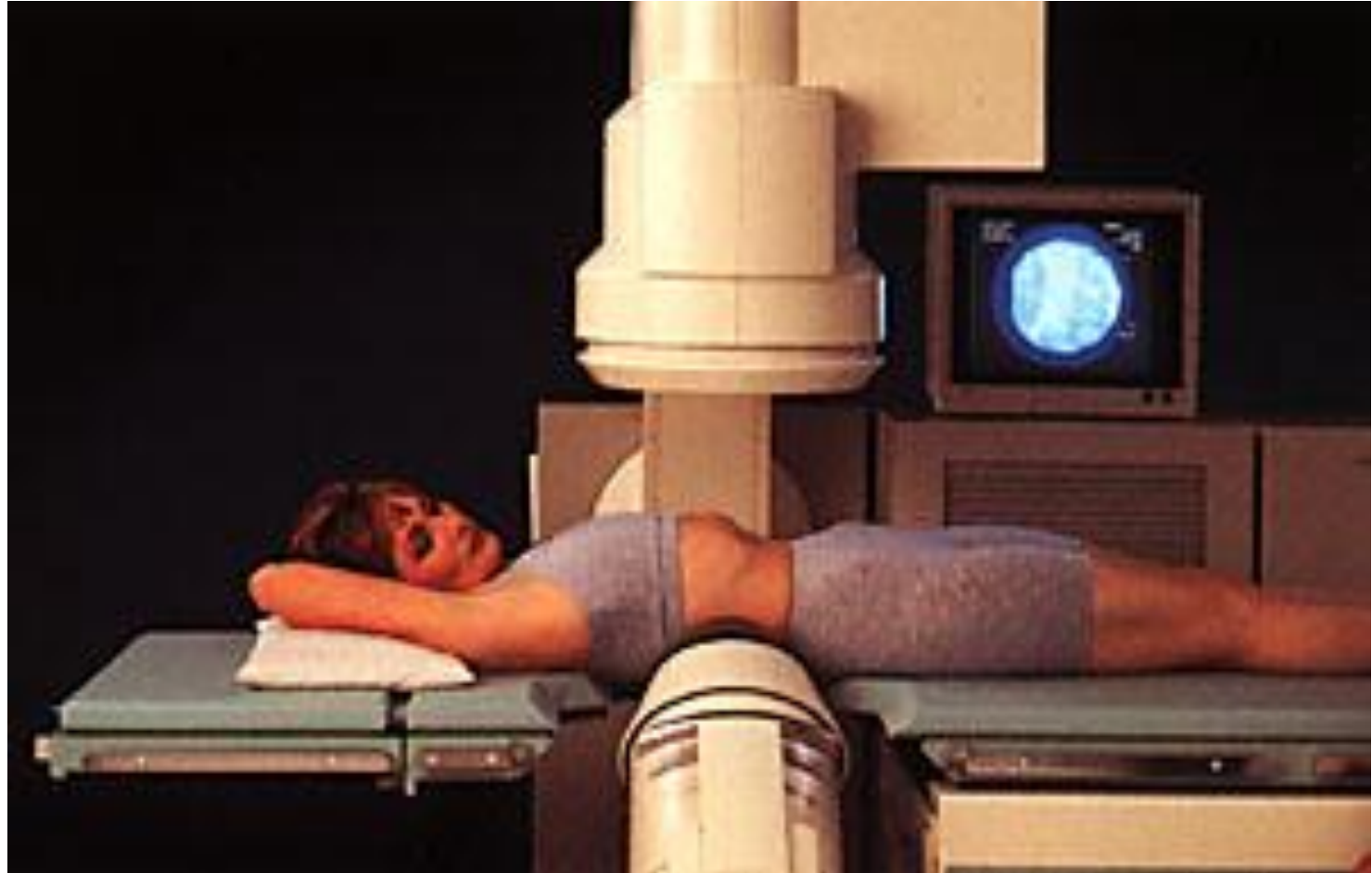- Conservative passage + Alpha Blocker (Flomax) + Hydration + NSAID (if Normal GFR)
 - Indications
 - Pain can be controlled with NSAID + Narcotic
 - No renal impairment
 - No Intractable Vomiting (aka pt not hypovolemic)
 - No sign of infection
 - No previous failed trials of conservative passage

ESWL

- Extracorporeal Shockwave lithotripsy
 - Indication:
 - <2cm renal or ureteric stone
 - Stone is localized by X-Ray.
 - Repeated shocks targeted to gradually fragment stone
 - Fragments passed in urine



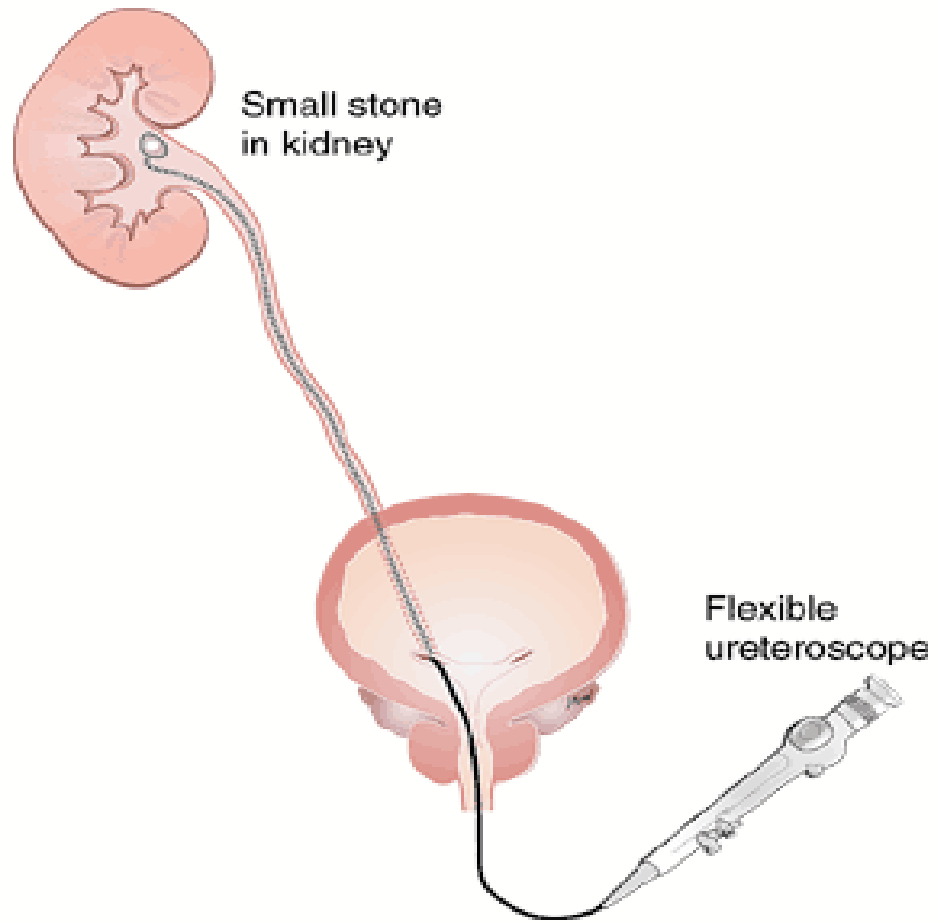
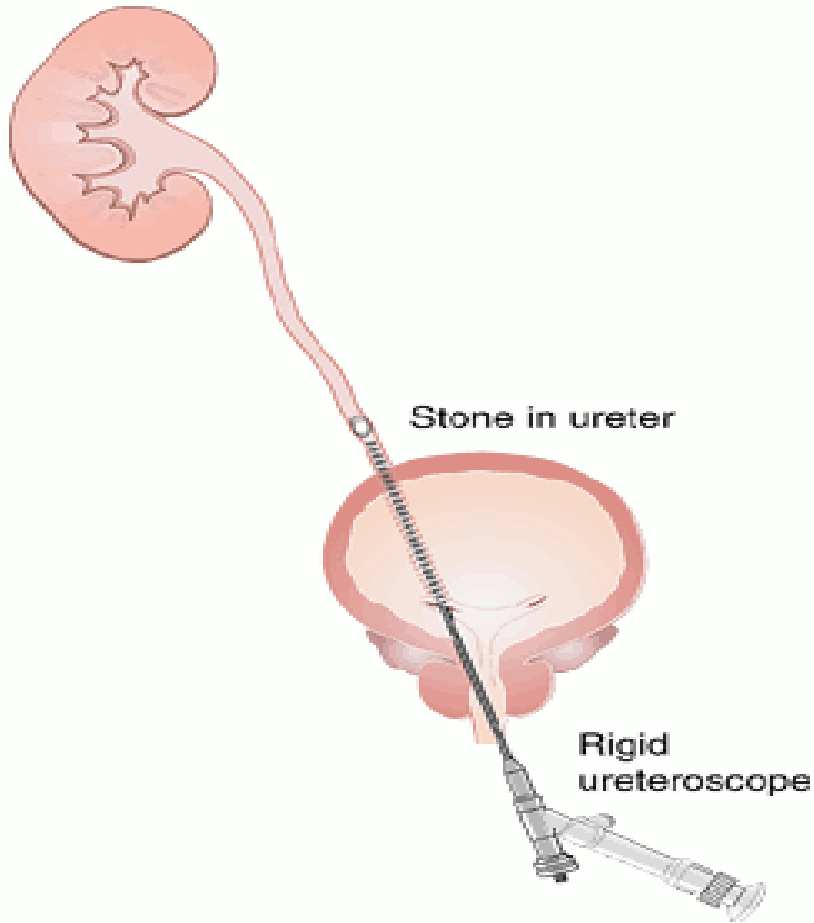
Extracorporeal Shock Wave Lithotripsy (ESWL)

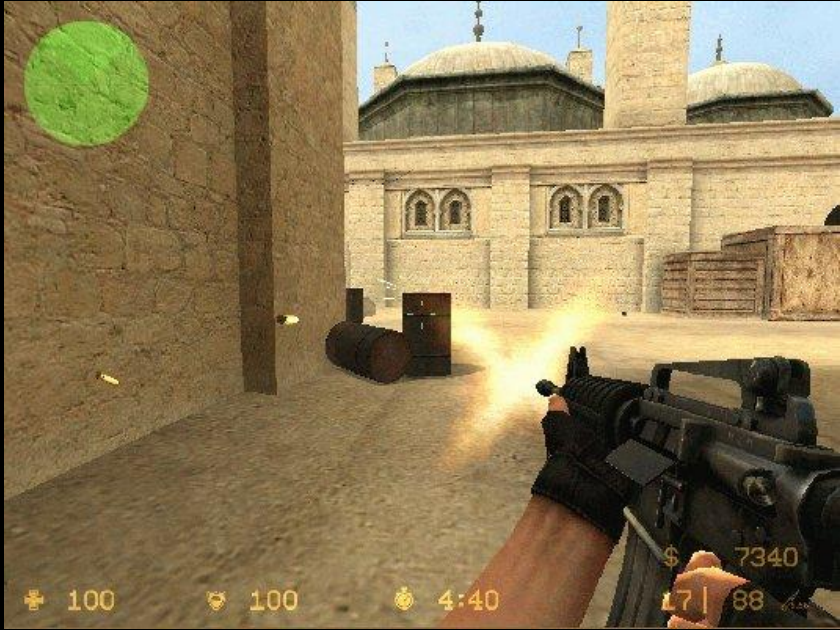
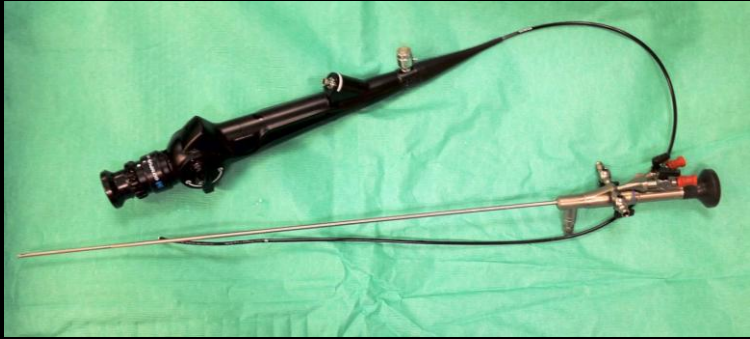
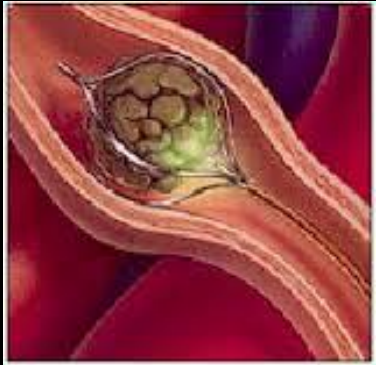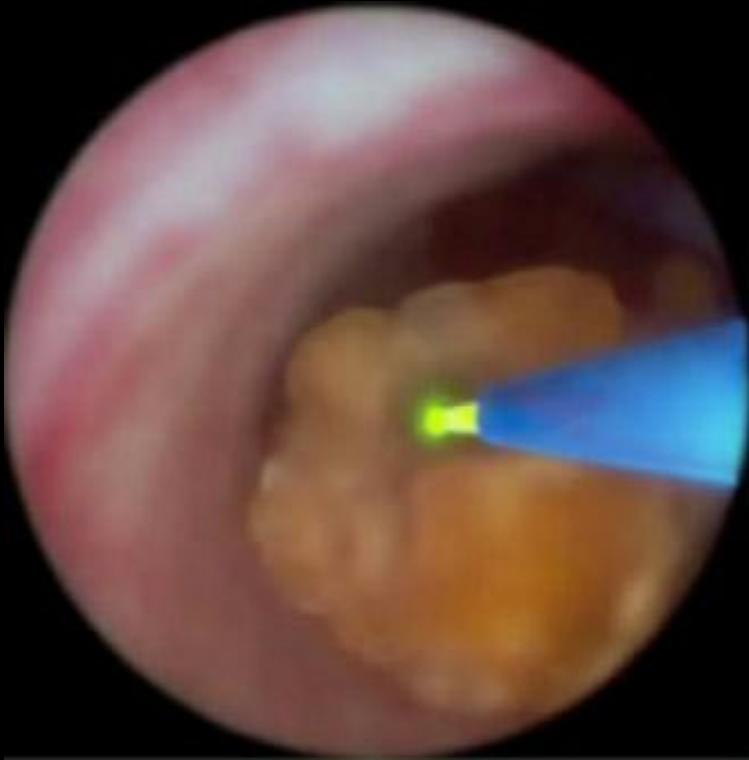Treating Stones

- Ureteroscopy
 - + Basket
 - If stone is small enough to adequately remove by basket
 - + Holmium Laser
 - If stone is 'impacted' or too large to basket out

Ureteroscopy

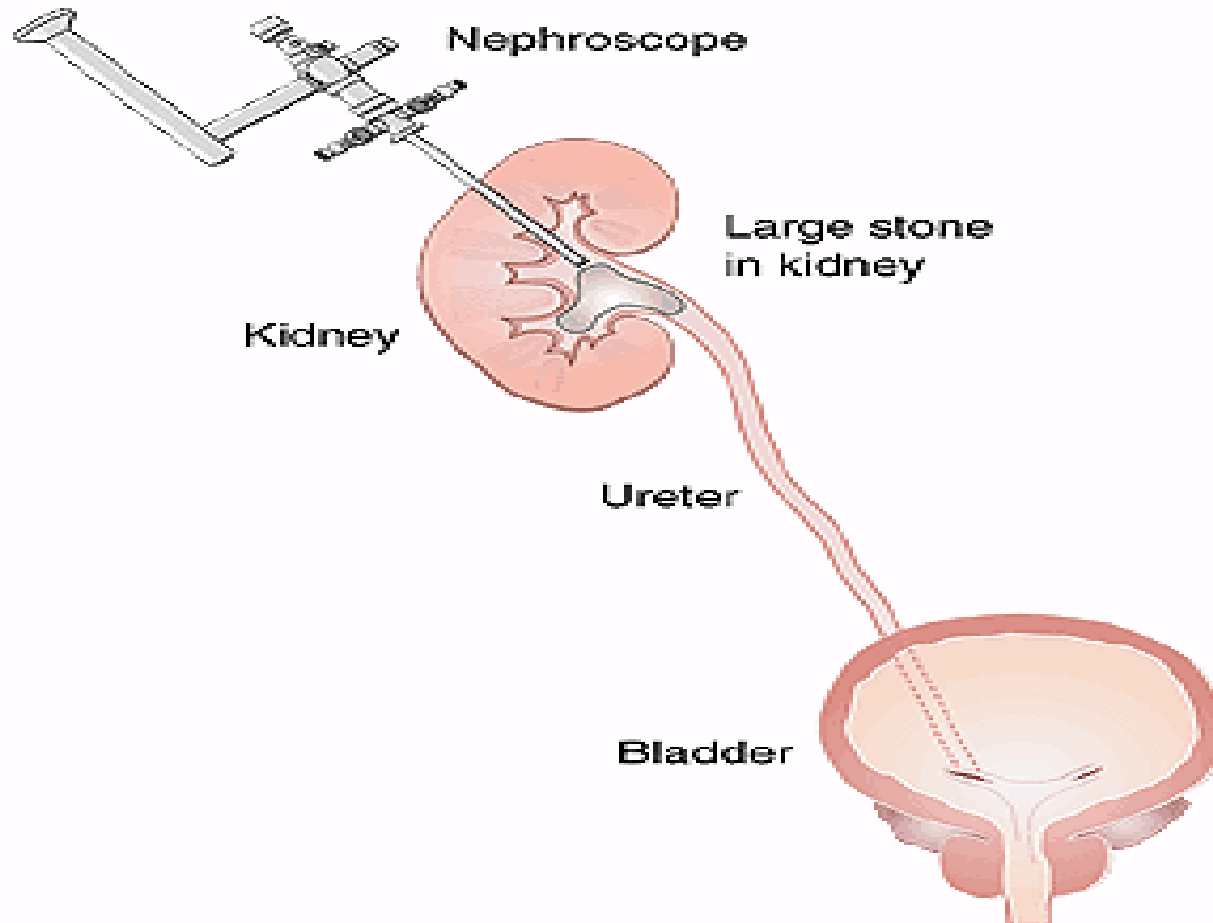




Treating Stones

- Percutaneous Nephrolithotomy
 - Indications
 - Large Proximal ureteric or renal calculi $>\sim 1-1.5\text{cm}$
 - Treatment of Staghorn Calculi
 - Risks:
 - Bleeding
 - Renal Perforation or Avulsion

PCNL



Renal Colic

Objectives

1. Give a differential diagnosis for acute flank pain including two life-threatening conditions
2. Describe the laboratory and radiologic evaluation of a patient with renal colic
3. Know 4 different kinds of kidney stones and the risk factors for stone formation
4. Know 3 indications for emergency drainage of an obstructed kidney

Urolithiasis

- Kidney Stone Diagnosis and Treatment Learning Resources

Evaluation and Medical Management of the Kidney Stone Patient
http://www.cua.org/userfiles/files/guidelines/ksm_2011_en.pdf



Student Resources and Materials

urology.med.ubc.ca

Home | Department of Urologi...
urology.med.ubc.ca
EPSON E-WebPrint - Print Clip Enable Flash printing

UBC a place of mind THE UNIVERSITY OF BRITISH COLUMBIA

Faculty of Medicine
Department of Urologic Sciences

Home About Patient Information Research Events & Newsletters Staff Faculty Donate Careers Links

Our Mission

To achieve and maintain excellence in urologic patient care, research and teaching.

Our Goals

The Department of Urologic Sciences will strive to:

- Provide state of the art, evidence-based healthcare delivery to regional, provincial, national and international communities through an integrated, interprofessional team.
- Support and strengthen the pillars of UBC's vision: people, learning, community service, research and internationalization.
- Provide a provincial hub for health research and education and policy making; focus on health as well as illness.
- Identify, design, conduct, analyze and report research relevant to the diseases of the genitourinary tract (prostate, kidneys, bladder, genitals).
- Translate basic science research evidence directly to clinical research and eventually improve clinical care, elevating these functions to an internationally superior level.
- Implement multidisciplinary and transdisciplinary partnerships within UBC, other universities, hospitals and all levels of government, to facilitate the mission.
- Become a sought-after destination for clinical and research trainees and scientists committed to the study and management of genitourinary diseases.
- Provide comprehensive undergraduate, graduate, postgraduate and continuing health education.
- Strengthen the entire Faculty of Medicine through its overall mission.

Announcements

- [Dr. Martin Gleave awarded Aubrey J. Tingle Prize](#)

Urology Grand Rounds & Other Upcoming Events

[Urology Grand Rounds Notice](#)
[View site & archives](#)

Sections

- [Bladder Care Centre](#)
- [Infertility](#)
- [Men's Health](#)
- [Prostate Centre and Oncology](#)
- [Pediatrics](#)
- [Stone Centre](#)
- [Transplantation and MIS](#)

Educational Programs

- [Residency Program](#)
- [Fellowship Program](#)
- [Undergraduate Program](#)

